

# IMMUNOHISTOCHEMICAL EXPRESSION OF WILM'S TUMOR (WT1) MARKER IN HISTOLOGICAL GRADES OF ORAL SQUAMOUS CELL CARCINOMA

<sup>1</sup>DANIAL QASIM BUTT, <sup>2</sup>FAROOQ AHMAD CHAUDHARY, <sup>3</sup>NAVEED MAZHAR BHATTI, <sup>4</sup>DANIAL KHALID, <sup>5</sup>AAMIR RAFIQ, <sup>6</sup>ZULEIKHA MALIK

## ABSTRACT

*Wilm's Tumor 1 (WT1) is a tumor suppressor gene located on the chromosome 11p13 that have been detected in variable neoplasm such as mesotheliomas and primary peritoneal serous and ovarian carcinomas. In this study we are determining the immunohistochemical expression of WT1 in oral squamous cell carcinoma (OSCC). One hundred cases of oral squamous cell carcinoma were considered and diagnosed in Department of Histopathology, Armed Forces Institute of Pathology (AFIP), Rawalpindi. Immunohistochemical marker WT1 were applied on the H/E stained slides. Immunohistochemical expression of WT1 was analyzed on sixty eight cases of well differentiated oral squamous cell carcinoma (WD-OSCC), twenty one cases of moderately differentiated oral squamous cell carcinoma (MD-OSCC) and eleven cases of poorly differentiated oral squamous cell carcinoma (PD-OSCC). Sixty three cases (63%) of OSCC samples demonstrated WT1 immunohistochemical expression with seventy four (74%) cases showing low WT1 expression and twenty six cases showing high WT1 expression. P value 0.024 significantly correlated with the histological grades of OSCC. WT1 is involved in the tumorigenesis of OSCC.*

**Key Words:** *Well differentiated Oral Squamous Cell Carcinoma, Moderately Differentiated, Poorly Differentiated.*

## INTRODUCTION

Squamous cell carcinoma (SCC) considerably occupies the highest percentage among the heterogeneous group of malignant cancers. It is the most common type of cancer in South Asian Countries like India, Srilanka, Pakistan and Bangladesh and contributes nearly one-fourth of all new cases of cancer.<sup>1</sup> OSCC is involved in

ninety percent of all the malignancies.<sup>2</sup> They initiate through rapid uncontrolled division of cancer epithelial cells and once matured gets infiltrated into the adjacent structures, or can disseminate to other organs (secondary metastasis). Most commonly affected sites are lip, tongue, buccal mucosa and floor of the mouth. The OSCC predominantly arises from the non-keratinized mucosa, with the most common sites involve are buccal mucosa accounting for 50% of all the oral cavity cancers, followed by tongue which accounts for 20% and lower alveolus 13%.<sup>3</sup> This disease is characterized clinically by signs and symptoms (ulcerated, exophytic growth). The early onset is painless as it becomes aggressive, it becomes painful and eventually bleeds if it traumatized and become secondarily infected. The prognosis and therapy strictly depend on the histological grades and correlated to rapid diagnosis.

Wilm's Tumor 1 (WT1) is a tumor suppressor gene located on the chromosome 11p13 that have been detected in variable neoplasms such as mesotheliomas and primary peritoneal serous and ovarian carcinomas.<sup>4</sup> WT1 gene contains 10 exons and spans around 50kb approximately generating 3 kb mRNA. The carboxyl terminal portion having four zinc finger motifs forming a domain for DNA binding and regulates the early growth response gene 1 family i.e. EGR1 and EGR2

<sup>1</sup> **For correspondence:** Dr Danial Qasim Butt, BDS, MPhil Oral Pathology (UHS), Senior Lecturer & Head of Department of Oral Pathology, Dental College, HITEC-IMS, Taxila Cantt, Email: drdaniel9@hotmail.com

<sup>2</sup> Dr Farooq Ahmad Chaudhary, BDS, MPH, MDPH (Malaysia), PhD (Scholar), Senior Lecturer and Head of Department of Community Dentistry, Dental College, HITEC-IMS, Taxila Cantt. email: chaudhary4@hotmail.com

<sup>3</sup> Dr Naveed Mazhar Bhatti, MHPE (Scholar), MSc Orthodontics, PGD Bioethics (SIUT), BDS, Associate Professor and Head of Department Orthodontics, Dental College, HITEC-IMS, Taxila Cantt. email: naveedbhatti@hotmail.com

<sup>4</sup> Dr Danial Khalid, BDS, MSc, Oral Biology Assistant Professor and Head of Department of Oral Biology, Dental College, HITEC-IMS, Taxila Cantt. email: drdaniel12@gmail.com

<sup>5</sup> Dr Aamir Rafiq, BDS, FCPS Prosthodontics, Assistant Professor and Head of Department of Prosthodontics, Dental College, HITEC-IMS, Taxila Cantt. email: aamir.rafiq84@yahoo.com

<sup>6</sup> Dr Zuleikha Malik, BDS, MPhil (Scholar) Dental Materials. MPhil Trainee of Dental Materials, Department of Dental Materials, National University of Medical Sciences, Rawalpindi. email: zuldian9@hotmail.com

**Received for Publication:** Dec 12, 2018

**First Revised:** Dec 30, 2018

**Approved:** Dec 31, 2018

proteins, indicative of its role as transcription factor.<sup>5</sup> 24 different isoforms are generated from alternative RNA splicing and RNA editing, it depends on the target site where WT1 is binding. WT1 down regulates the EGFR<sup>6</sup>, PAX 2 and IGF-2.<sup>7</sup> The addition of 68 amino acid amino terminal portion has a slight effect on the transcription.<sup>8</sup> In comparison with the shorter versions of amino terminal, it increases activation potential.<sup>9</sup> Spliced exon 5 has the repressing effect of WT1 on some promoters<sup>10</sup>. WT1 17AA isoform has shown its role in cell division and cell survival. Its mutation causes neoplasm of the kidney in 1 of 10,000 infants. Alteration of WT1 leads to Wilm's tumor and Denys-Drash syndrome, presented both in sporadic and hereditary forms. The WT1 protein has been documented for its binding capability with the cellular components e.g. p53<sup>11</sup>. Previous studies on breast cancer have provided the fact of Wilm's tumor oncogenic role<sup>12</sup>. WT1 overexpression has been documented in variety of cancers like urinary tract cancers, cancer of male genital organs, malignant melanomas and pancreatic cancers. Many reported evidences reveal the role of WT1 in cancer cells proliferation and at present a cancer therapy in the form of WT1 peptide based immunotherapy has been suggested as a capable method of dealing with the cancers<sup>13</sup>. The purpose of the study was to demonstrate the immunoexpression of WT1 in the histological grades of OSCC which can be beneficial in using WT1 peptide based immunotherapy in treating different patients of OSCC.

## METHODOLOGY

The Descriptive study was carried out in the Department of Histopathology, Armed Forces Institute of Pathology (AFIP, Rawalpindi), Ethical approval was taken from the respective institute. The sample size was 100 cases was calculated by WHO calculator<sup>13</sup> ( $n = Z^2 PQ / d^2$ , where  $n$  = desired sample size,  $Z$  = standard normal deviate, corresponding to 95% confidence level,  $P$  = proportion in the target population estimated to have a particular characteristic,  $Q = 1 - P$  = proportion in the target population not having the particular characteristics) and  $d$  = degree of accuracy required,  $Z_2 = 3.8416$ ,  $P = 7\%$  (0.07),  $Q = 1 - P$ ,  $d = 0.0025$ ). The sampling technique was Non Probability convenience sampling. Freshly diagnosed cases or archival tissue blocks of OSCC of all the grades were recruited from different hospitals. All age groups, both genders involving the oral cavity diagnosed at AFIP Rawalpindi were included. Poorly fixed specimen, necrosed or autolysed tissue samples and tumors with scanty tissue were excluded and previously treated cases of OSCC were also excluded. Quantitative variables were age and gender while the Qualitative variables were histological grades, immunohistochemical (IHC) expression of WT1 and Immunohistochemical score. Percentage of

positively reactive tumor cells was measured as <5%, 5 to 50% 51 to 75%, and > 75%. Similar grading scales have previously been used in the immunohistochemical expression studies of WT1<sup>14,15</sup>. The expression pattern was organized into high expression and low expression groups and their relationship were correlated with histological grade of differentiation<sup>16</sup>.

Tissues were prepared for microscopic examination. The tissue processing was start with the fixation of the surgical specimen or biopsy using buffered formalin (10%). All the representative sections from the surgical specimen were taken and processed in labeled plastic cassettes with perforated walls. These were then placed in automatic tissue processor Tissue Tek VIP-5 processor. The processing involved dehydration using increasing strengths of alcohol, clearing in which the alcohol was replaced by xylene at 38°C, followed by impregnation of the tissue with molten paraffin wax at temperature of 52-55°C. Casting or blocking was then carried out using Tissue Tek Embedding Console system, filling metal moulds with fresh molten wax and was allowed to cool. Finally the cooled blocks were trimmed and very thin sections (3-5 microns) were cut using Accu Cut Rotary Microtome SRM 200-1. The sections were picked up on clean and labeled frosted glass slides and were stained in Varistain Multiproy slide stainer. The immunohistochemistry was then applied using the indirect method, It is a two-step method with an unlabeled primary antibody (first layer) reacting with tissue antigen followed by application of secondary labelled antibody (second layer) reacting with primary antibody. This method has adequate sensitivity and second layer antibody can be labeled with a fluorescent dye or enzyme.

The information collected in the form of variables on specially designed data collection proforma was analyzed using SPSS version 17.0. Descriptive statistics were used to describe the data. Mean and standard deviation was used to describe numeric variables like age and gender. Categorical variables were analyzed by calculating frequency and percentages. Immunomarker result and their association with the histological grade with the help of Chi square test was carried out. P value significance was set at < 0.05.

## RESULTS

The results are made on one hundred cases of OSCC of different histological grades. There were fifty (53%) males and forty seven (47%) females, with a male to female ratio of 1.12:1. Mean age was 57.11 years with SD  $\pm 14.6$ . Sixty eight (68%) were WD-OSCC, with twenty one (21%) were MD-OSCC and eleven (11%) were PD-OSCC. The tongue was found in fifty seven cases (57%), followed by buccal mucosa thirty three cases (33%), lower lip six cases (6%), lower jaw two

TABLE 01: IMMUNOEXPRESSION OF WT1 PERCENTAGE OF STAINED CELLS IN WD-OSCC

Percentage of stained cells	Intensity	
	Low	High
0	14	-
<5	16	-
5 – 50	20	-
51 – 75	-	19
>75	-	4

TABLE 2: IMMUNOEXPRESSION OF WT1 PERCENTAGE OF STAINED CELLS IN MD-OSCC

Percentage of stained cells	Intensity	
	Low	High
0	12	-
<5	2	-
5 – 50	1	-
51 – 75	-	1
>75	-	-

TABLE 3: IMMUNOEXPRESSION OF WT1 PERCENTAGE OF STAINED CELLS IN PD-OSCC

Percentage of stained cells	Intensity	
	Low	High
0	06	-
<5	02	-
5 – 50	01	-
51 – 75	-	02
>75	-	-

TABLE 4: RELATION OF WT1 IMMUNOEXPRESSION IN HISTOLOGICAL GRADES OF OSCC

Tumor Differentiation	WT1 Expression		P Value
	Low	High	
WD-OSCC	45	23	
MD-OSCC	20	02	0.024*
PD-OSCC	09	01	

\*Significant

cases (2%), maxillary gingiva one case (1%) and hard palate one case (1%). WT1 was found weak or absent in the basal layer and in the infiltrating nest of cells. IHC of WT1 in OSCC with the percentage of stained cells were investigated in all of the histological grades of OSCC.

**WD-OSCC**

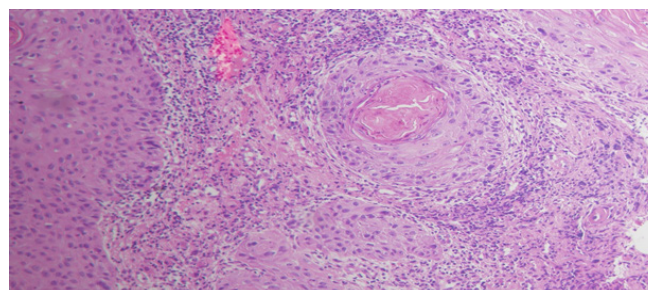


Fig 1: H/E staining of WD-OSCC at 10X power magnification, section shows nests of tumor cells infiltrating from the basal cell layer, and keratin pearl formation along with chronic inflammatory cells in the surrounding stroma.

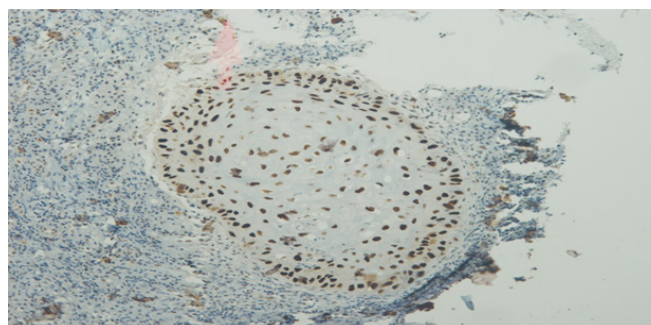


Fig 2: Immunohistochemical staining of WT1 at 10X power magnification showing nuclear staining with a slight weak staining of cytoplasm.

Fifty four cases showed the positivity out of sixty eight cases of WD-OSCC, with fourteen cases (20.5%) showed 0 reactivity, sixteen cases (23.5%) showing < 5 % of stained cell with and twenty cases (29.05%) of 5-50%, nineteen cases (27.9%) showed and four cases (5.8%) (Figure 1 and 2) were above the 75% stained cells (as shown in the table no.1)

**MD-OSCC**

Four cases (19%) showed the positivity out of twenty one cases of MD-OSCC, with seventeen cases (80.9%) showed 0 reactivity, two cases (9.5%) showing < 5 % of stained cell with and one case (4.7%) of 5-25% each with 1+ nuclear reactivity, while only one case (4.7%) showed 51-75% of stained cells (as shown in the table no.2).

**PD-OSCC**

Five cases (45.4%) showed the positivity out of eleven cases of PD-OSCC, with six cases (54.5%) showed 0 reactivity, two cases (18%) showing < 5 % of stained cells with and one case (9%) of 5-50%, two cases (18.18%) showed 51-75% of stained cells (as shown in the Table no.3).

79.4% (54 cases) of positivity in WD-OSCC (68 cases), 19% (4 cases) positivity in MD-OSCC (21 cases)

and 45.4% (5 cases) positivity in PD-OSCC (11 cases).

The expression pattern was organized into two groups; high expression and low expression and their relationship was correlated with histological grade of differentiation (as shown in Table no.4).

WT1 immunoexpression was found correlated with the histological differentiation of OSCC and with the age parameter ( $P$  value 0.004), However no significant correlation was found with the gender and tumor site ( $P$  value 0.8 and 0.6 respectively).

## DISCUSSION

In normal epithelium, there is continuous renewal of cells by the mitotic division at the basal cell layer. These cell migrate to the surface of the epithelium to replace the cells that are shed. In WD-OSCC, same process occurs where the cancer nests proliferate and infiltrate from the basal layer into the underlying tissue. WT1 was observed expressed in the cancer nests suggesting its role in neoplastic proliferation of cancer nests.<sup>17</sup> Wilm's tumor 1 (WT1) is a tumor suppressor gene responsible for a kidney neoplasm in children. In oral SCC, the alliance of WT1 protein and Ribonucleoprotein particles (RNPs) suggested its involvement in RNA metabolism by the shuttling of WT1 protein between nucleus and cytoplasm.<sup>18</sup>

Oji et al.<sup>19</sup> in a study of esophageal squamous cell carcinoma observed the overexpression of WT1 protein in esophageal proliferating tumor nests in the underlying connective tissue infiltrating from the basal layer of the epithelium. The expression was weak to moderate at the basal cell layer. The study suggested significant correlation with PD-OSCC as more expression was observed when the tumor cells differentiated from well differentiated to poorly differentiated tumor cells. Similar expression of WT1 in basal cell layers and infiltrating tumor nests were observed in our study. WT1 overexpression was observed more in the WD-OSCC in this study. Mikami et al.<sup>13</sup> investigated the role of WT1 protein in OSCC and found positive expression of WT1 in well differentiated tumor cells and suggested its role in tumor cell proliferation. Similarly Fattahi et al.<sup>20</sup> observed the same phenomenon and suggested its strong role in tumorigenesis. Our results also showed the positivity of WT1 in each of the histological grade of OSCC suggesting the tumorigenesis role. More detailed studies should be carried out worldwide of IHC expression of WT1 in OSCC. Previous studies have proposed its role in tumorigenesis and its detection in various cancers such as leukemia, breast cancers, sarcomas<sup>21,22</sup> and lung cancers [13]. These cancers expressed WT1 and were treated with WT1 antisense oligomers. Tsuboi et al.<sup>23</sup> used WT1 peptide-based immunotherapy, in which anti WT1 vaccinations caused increase in the

WT1-specific cytotoxic-T lymphocytes which reduced the leukemic blast cells in patients with leukemia. More studies are needed to establish conclusive role of WT1 expression in OSCC and immunotherapy as treatment in treating patients of OSCC.

## CONCLUSION

WT1 expression results suggested a strong role in tumorigenesis, which is consistent with other studies. New WT1 peptide based oligomers (vaccinations) are being used in immunotherapy for the direct tumor cell killing and in future may be tried on the cases of oral squamous cell carcinoma.

## REFERENCES

- 1 Awan KH, Patil S. Association of smokeless tobacco with oral cancer—Evidence from the South Asian studies: A systematic review. *J Coll Physicians Surg Pak.* 2016;26(9):775-80.
- 2 Markopoulos AK: Current aspects on oral squamous cell carcinoma. *The open dentistry journal* 2012; 6:126-28.
- 3 Tandon P, Dadhich A, Saluja H, Bawane S, Sachdeva S: The prevalence of squamous cell carcinoma in different sites of oral cavity at our Rural Health Care Centre in Loni, Maharashtra—a retrospective 10-year study. *Contemporary Oncology* 2017; 21(2):178-81.
- 4 Megias-Vericat JE, Herrero MJ, Rojas L, Montesinos P, Bosó V, Moscardó F, Martínez-Cuadrón D, Poveda JL, Sanz MÁ, Aliño SF. A systematic review and meta-analysis of the impact of WT1 polymorphism rs16754 in the effectiveness of standard chemotherapy in patients with acute myeloid leukemia. *The pharmacogenomics journal.* 2016;16(1):30-33.
- 5 Lu J, Gu Y, Li Q, Zhong H, Wang X, Zheng Z, Hu W, Wen L. Wilms' tumor 1 (WT1) as a prognosis factor in gynecological cancers: A meta-analysis. *Medicine.* 2018;97(28).
- 6 Dressler GR, Deutsch U, Chowdhury K, Nornes HO, Gruss P: Pax2, a new murine paired-box-containing gene and its expression in the developing excretory system. *Development* 1990;109(4):787-95.
- 7 Drummond IA, Madden SL, Rohwer-Nutter P, Bell GI, Sukhatme VP, Rauscher FJ: Repression of the insulin-like growth factor II gene by the Wilms tumor suppressor WT1. *Science* 1992;257(5070):674-78.
- 8 Bruening W, Pelletier J: A non-AUG translational initiation event generates novel WT1 isoforms. *Journal of Biological Chemistry* 1996; 271(15):8646-54.
- 9 Scharnhorst V, Dekker P, van der Eb AJ, Jochemsen AG: Internal translation initiation generates novel WT1 protein isoforms with distinct biological properties. *Journal of Biological Chemistry* 1999; 274(33):23456-62.
- 10 Hewitt SM, Fraizer GC, Wu Y-J, Rauscher FJ, Saunders GF: Differential function of Wilms tumor gene WT1 splice isoforms in transcriptional regulation. *Journal of Biological Chemistry* 1996; 271(15):8588-92.
- 11 Agrawal S. The Wilms' tumor (WT1) gene: Methods and protocols. *The Indian journal of medical research.* 2018;147(6):622.
- 12 Lopotová T, Polák J, Schwarz J, Klamová H, Moravcová J. Expression of four major WT1 splicing variants in acute and chronic myeloid leukemia patients analyzed by newly developed four real-time RT-PCRs. *Blood Cells, Molecules, and Diseases.* 2012 Jun 15;49(1):41-7.
- 13 Mikami T, Hada T, Chosa N, Ishisaki A, Mizuki H, Takeda Y.

- Expression of Wilms' tumor 1 (WT1) in oral squamous cell carcinoma. *Journal of Oral Pathology & Medicine*. 2013;42(2):133-9.
- 14 Shimizu M, Toki T, Takagi Y, Konishi I, Fujii S: Immunohistochemical detection of the Wilms' tumor gene (WT1) in epithelial ovarian tumors. *International journal of gynecological pathology* 2000; 19(2):158-63.
  - 15 Goldstein NS, Uzieblo A: WT1 immunoreactivity in uterine papillary serous carcinomas is different from ovarian serous carcinomas. *American journal of clinical pathology* 2002; 117(4):541-45.
  - 16 Fan CC, Wang TY, Cheng YA, Jiang SS, Cheng CW, Lee AY, Kao TY. Expression of E-cadherin, Twist, and p53 and their prognostic value in patients with oral squamous cell carcinoma. *Journal of cancer research and clinical oncology*. 2013;139(10):1735-44.
  - 17 Fattahi S, Rahmani SZ, Vosoughhosseini S and Rahmani SP. Configuring the Expression of Wilms Tumor 1 in Oral Squamous Cell Carcinoma and Its Relationship with Clinicopathologic Features. *J Dent App*. 2016; 3(4): 349-52.
  - 18 Kijima N, Hashimoto N, Chiba Y, et al. Functional Roles of Wilms' Tumor 1 (WT1) in Malignant Brain Tumors. In: van den Heuvel-Eibrink MM, editor. *Wilms Tumor* [Internet]. Brisbane (AU): Codon Publications; 2016 Mar. Chapter 15.
  - 19 Oji Y, Inohara H, Nakazawa M, Nakano Y, Akahani S, Nakatsuka Si, Koga S, Ikeba A, Abeno S, Honjo Y: Overexpression of the Wilms' tumor gene WT1 in head and neck squamous cell carcinoma. *Cancer science* 2003; 94(6):523-29.
  - 20 Fattahi S, Rahmani SZ, Vosoughhosseini S and Rahmani SP. Configuring the Expression of Wilms Tumor 1 in Oral Squamous Cell Carcinoma and Its Relationship with Clinicopathologic Features. *J Dent App*. 2016; 3(4): 349-352.
  - 21 Loeb DM, Evron E, Patel CB, Sharma PM, Niranjana B, Buluwela L, Weitzman SA, Korz D, Sukumar S: Wilms' tumor suppressor gene (WT1) is expressed in primary breast tumors despite tumor-specific promoter methylation. *Cancer research* 2001; 61(3):921-25.
  - 22 Miyoshi Y, Ando A, Egawa C, Taguchi T, Tamaki Y, Tamaki H, Sugiyama H, Noguchi S: High expression of Wilms' tumor suppressor gene predicts poor prognosis in breast cancer patients. *Clinical cancer research* 2002; 8(5):1167-71.
  - 23 Tsuboi A, Oka Y, Ogawa H, Elisseeva OA, Tamaki H, Oji Y, Kim EH, Soma T, Tatekawa T, Kawakami M: Constitutive expression of the Wilms' tumor gene WT1 inhibits the differentiation of myeloid progenitor cells but promotes their proliferation in response to granulocyte-colony stimulating factor (G-CSF). *Leukemia research* 1999; 23(5):499-505.

#### CONTRIBUTIONS BY AUTHORS

- |                                  |                                                        |
|----------------------------------|--------------------------------------------------------|
| <b>1 Danial Qasim Butt:</b>      | Topic selection, Literature search, write up, results. |
| <b>2 Farooq Ahmad Chaudhary:</b> | Literature review, write up, results.                  |
| <b>3 Naveed Mazhar Bhatti:</b>   | Literature review, data analysis, references.          |
| <b>4 Danial Khalid:</b>          | Write up, references.                                  |
| <b>5 Aamir Rafiq:</b>            | Literature review, data analysis.                      |
| <b>6 Zuleikha Malik:</b>         | Write up, references.                                  |

## CORRIGENDUM

Ref: PODJ Vol 38, September 2018: Consistency measurements of three commercial and five novel experimental vinyl polysiloxane (VPS)

Name of authors and addresses in the said article are as follows:

- |                              |                                                          |
|------------------------------|----------------------------------------------------------|
| 1. Shahab Ud Din:            | Asst Prof Dentistry PIMS, Islamabad                      |
| 2. Sadia Khilid:             | Dentistry Department, PIMS                               |
| 3. Sheharyar Akthar Khokhar: | Asst Proessor Dentistry, PIMS                            |
| 4. Sadiq Ali:                | Asst Prof Central Park Medical College, Rawalpindi       |
| 5. Shahreen Zahid Khan:      | Asst Prof Army Medical College, Rawalpindi               |
| 6. Mangala Patel:            | Prof Dental Physical Sciences, London School of Medicine |