

IMPACTED MAXILLARY CANINES IN JORDANIAN POPULATION

¹MOATH MOMANI, ²REYAD ABUODEH, ³AHMAD ADWAN, ⁴ALI AUTOOM, ⁵AHMAD TARAWNEH

SUMMARY

The maxillary canine is the last tooth to erupt with a primary predecessor so it is susceptible to environmental influences that may affect its eruption leading to its impaction.

Emphasis of this study was on their management. However, the general principles of diagnosis and treatment can be applied to both the maxillary and the mandibular teeth.

Literature about maxillary canines impaction in jordanian population was searched and all data available were recorded & analyzed.

Impacted maxillary canines are the second most frequently impacted teeth after the third molars, with a prevalence ranging from approximately 1% to 3%. The prevalence of impacted canines in jordanian population is estimated to be 3%. Among patients having maxillary canine impactions, females are more than twice affected in comparison to males. Impacted canines are found palatally in 85% of cases and buccally/labialy in 15%, and unilateral in 92% of cases. There is some evidence that patients with class II, division 2 malocclusions and tooth aplasia may be at higher risk to the development of an ectopic canine.

Maxillary canines are important aesthetically and functionally, but they are very difficult and time consuming to treat. And require an accurate diagnosis and localization. Moreover, impacted canines vary greatly in the inclination and location and can lead to resorption of neighboring incisors.

Key Words: *Impacted maxillary canines, frequency, jordanian population, diagnosis, treatment*

INTRODUCTION

Impaction is defined as a failure of tooth eruption at its appropriate site in the dental arch, within its normal period of growth.¹

The maxillary canine is the last tooth to erupt with a primary predecessor, so it is susceptible to environmental influences that may affect its eruption leading to its impaction. Maxillary canines are important aesthetically and functionally, but they are very difficult and time consuming to treat. And require an accurate diagnosis and localization. Moreover, impacted canines vary greatly in the inclination and location and can lead to resorption of neighboring incisors.^{2,3}

So the primary detection of the canine impaction is very important to achieve the best possible treatment results with the minimal complications.

Normal development of the maxillary canine

Maxillary canines have the longest period of development, as well as the longest and most tortuous course to travel from their point of formation, lateral to the piriform fossa, until they reach their final destination in full occlusion.⁵

The canine remains high in the maxilla just above the root of the lateral incisor with the crown directed mesially until the crown is calcified. It then follows a mesial path of movement with increasing mesial inclination (first rapidly and then more slowly) until a maximum point is reached when it reaches the distal aspect of the lateral incisor root at about 9 years of age. After that the canine takes a more vertical position and is guided by the lateral incisor root until it is fully erupted.⁴

If the lateral incisors are congenitally missing, the canine may erupt in a mesial direction until it comes into contact with the distal aspect of the central incisor root and erupts into the lateral incisor space.⁶

Etiology of maxillary canine impaction

The etiology of maxillary canine impaction is still obscure, but probably is multifactorial.² With a wide variety of systemic and local etiologies summarized in (Table 1). Systemic factors include: endocrine diseases, febrile illnesses and irradiation.

These environmental factors may contribute to this anomaly during the long, tortuous eruption path of a canine.⁵

The most common causes for canine impactions are usually localized and are the result of any one, or combination of the multiple factors.⁵

¹ All authors from Royal Medical Services, Amman - Jordan

Received for Publication: April 5, 2018

Revised: June 26, 2018

Approved: June 28, 2018

Palatal and buccal canine impactions are considered to be completely different entities. Buccal canine impaction is thought to be a form of crowding. Nevertheless, given time and space this tooth will usually erupt in the oral cavity.⁷ Insufficient space in the upper arch for the eruption of the maxillary canine may result in a tooth erupting buccally or its impaction.^{2,7}

The etiology of palatal canine impaction is not very clear. Some authors believe, contrary to buccal impaction, that the presence of excess space in the upper arch could lead to palatal canine impaction by allowing the canine to cross back from the buccal to the palatal side.⁷

Becker and co-workers suggested that canine impaction can be explained by the lack of guidance by the roots of the lateral incisors during the early stages of canine eruption. It seems that the presence of the lateral incisor root with the right length, formed at the right time, are important variables needed to guide the mesially erupting canine in a more favorable distal and incisal direction.

Miller reported a high incidence of impacted canines associated with small, peg-shaped lateral incisors.^{5,6,7} Delayed exfoliation of the primary canine may result in impaction because of the continued palatal movement of the permanent successor. However, Thilander and-Jacobsson considered this to be a consequence rather than a cause of impaction.^{2,5}

Other factors that are associated with canine impaction may include: early loss of the primary canine⁵, ankylosis^{2,5}, odontomes or supernumerary teeth², the presence of an alveolar cleft, cystic or neoplastic formation, dilaceration of the root, iatrogenic origin and idiopathic conditions with no apparent cause.⁵

Diagnosis of maxillary impacted canines

It is important to locate the exact position of the impacted maxillary canine. Localization of the unerupted canine involves inspection, palpation and radiographic assessment.

Clinical Evaluation

It has been suggested that the following clinical signs might be indicative of canine impaction: Delayed eruption of the permanent canine or prolonged retention of the deciduous canine beyond 14 to 15 years of age. Absence of a normal labial canine bulge; Presence of a palatal bulge may indicate that the crown is palatally impacted.^{2,5} Delayed eruption, distal tipping, or migration of the lateral incisor.^{2,5}

Radiographic Localization of the Impacted Tooth

After the age of 11 radiographs are indicated in all individuals with unerupted and non- palpable canines.²

Although various radiographic exposures including

TABLE 1: ETIOLOGIC FACTORS OF IMPACTED CANINES

| Genetics | Local Environmental | Systemic Environmental |
|-----------------------|-------------------------------------------------|------------------------|
| Heredity | Prolonged retention of primary teeth | Endocrine deficiency |
| Malposed tooth germ | Reduced root length of adjacent lateral incisor | Febrile diseases |
| Shortened arch length | Ankylosis of permanent canine | |
| Alveolar cleft | Degree of dental canine root to resorb | |
| | Small or congenitally missing lateral incisors | |

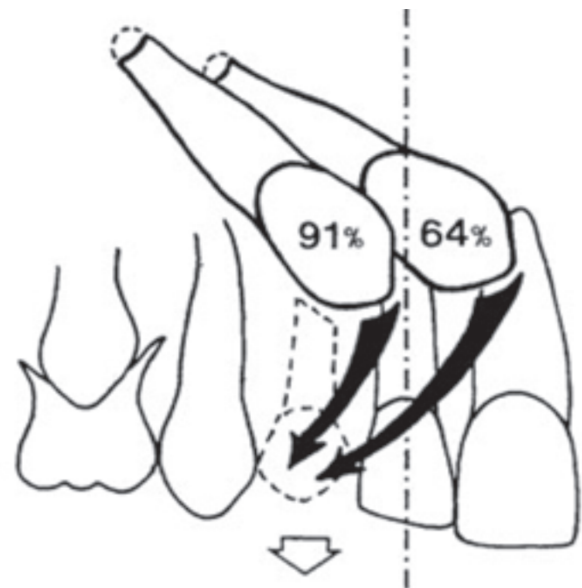


Fig 1:

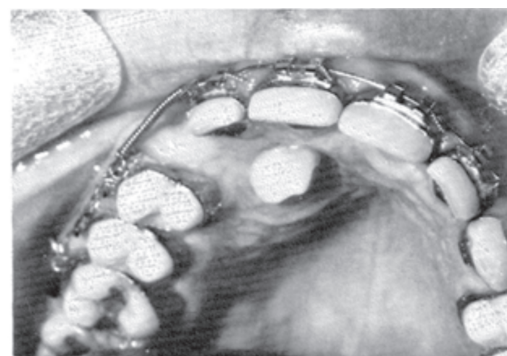

Fig 2: Palatally impacted canine surgically exposed and left to erupt on its own.

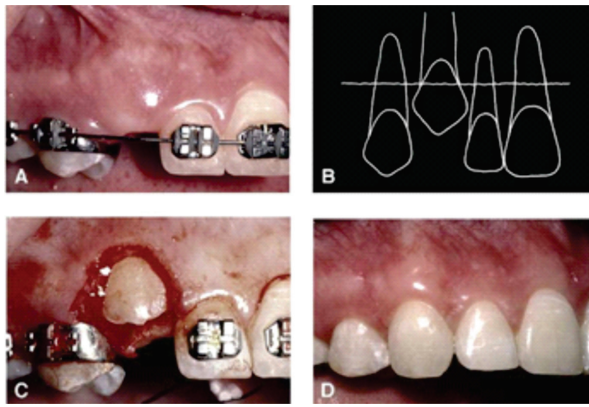


Fig 3: Patient had impacted maxillary right canine
 A, Space was created orthodontically, but tooth did not erupt.
 B, Tooth was labially positioned, coronal to mucogingival junction, and there was sufficient gingiva in area.
 C, simple excisional procedure was used to uncover it.
 D, After orthodontic eruption, relationship of gingival margins relative to adjacent teeth was normal with adequate zone of gingiva.

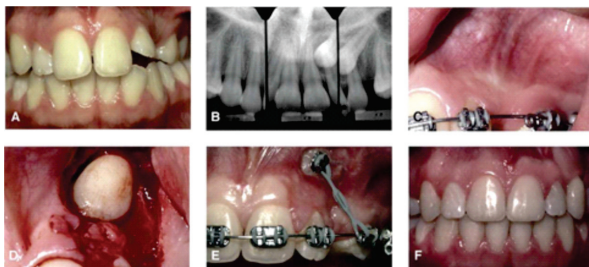


Fig 4: A, Patient had impacted maxillary left canine,
 B, Buccal object rule indicated tooth was labial, c,
 Teeth were initially aligned, any of the 3 techs Is acceptable. However, cusp tip was positioned above mucogingival junction & was mesial, D, Apically positioned flap technique was chosen. E, tooth was gradually moved distally after healing, F, placed in the correct position.

occlusal films, panoramic views, and lateral cephalograms can help in evaluating the position of the canines, in most cases periapical films are uniquely reliable for that purpose.⁵

Periapical films: A single periapical film provides the clinician with a two-dimensional representation of the dentition. In other words, it would relate the canine to the neighboring teeth both mesiodistally and superoinferiorly. To evaluate the position of the canine buccolingually, a second periapical film should be obtained.⁵

Occlusal film: These also help determine the buccolingual position of the impacted canine in conjunction

with the periapical films, provided that the image of the impacted canine is not superimposed on the other teeth.^{2,5}

Extraoral films

Frontal and lateral cephalograms can sometimes be of aid in determining the position of the impacted canine, particularly its relationship to other facial structures, such as the maxillary sinus and the floor of the nose.

Panorex films are also used to localize impacted teeth in all three planes of space, much the same as using two perapical films in the tube-shift method, with the understanding that the source of radiation comes from behind the patient; thus, the movements are reversed for position.⁵

Computerized tomography (CT) is very useful to predict the exact position of the canine, the degree of crowding, incisor resorption and the width of the dental follicle.²

This technique comprises several technologies that use data from computer-aided design files to produce physical models which gives a 3D model.⁵

Preventive & interceptive practices of maxillary canine impaction

If the clinician detects early signs of ectopic eruption of the canines, an attempt should be made to prevent their impaction & the possible sequelae, selective extraction of the primary canines as early as 8 or 9 years of age has been suggested by Williams as an interceptive approach to canine impaction in Class I uncrowded cases.

Ericson and Kurol¹⁰ suggested that removal of the primary canine before the age of 11 years will normalize the position of the ectopically erupting permanent canines in 91% of the cases if the canine crown is distal to the midline of the lateral incisor. On the other hand, the success rate is only 64% if the canine crown is mesial to the midline of the lateral incisor; this means that the more mesial the permanent canine is to the midline of the lateral incisor, the less likely the chance for spontaneous eruption following extraction of the primary canine. (Fig 1)

Ericson & Kurol suggest as well that extraction of the primary canine is the treatment of choice in the age group from 10-13 years when the erupting maxillary canine has a palatal ectopic path of eruption provided that the diagnosis of male ruption is done early & that the extraction treatment is done in time, when a favorable effect of treatment occurs, the change in position & path of eruption will be observed at least 12 months after extraction of the primary canines, if no

improvement can be found at that time, normalization isn't to be expected & alternative treatment should be considered.

Treatment alternatives

- No treatment.
- Auto transplantation of the canine.
- Extraction of the impacted canine and movement of the first premolar in the canine's position.
- Extraction of the canine & movement of the whole buccal segment mesially to close the residual space.
- Extraction of the impacted maxillary canine with simultaneous implant placement.
- Prosthetic replacement of the canine.
- Surgical exposure of the canine and orthodontic treatment to bring the tooth into the line of occlusion.⁵

1. Auto transplantation of the canine

Usually confined to cases where no alternatives are available, sufficient space should exist to accommodate the canine within the arch & occlusion, sometimes orthodontic treatment is performed prior to transplantation.

Therefore transplantation could be a treatment of choice when the following specific criteria are met:

- Age (young patients with half-developed to three quarter-developed roots).
- Extra-alveolar time less than 30 minutes.
- Minimal flexible splinting.
- Absence of trauma to the PDL.
- Endodontic treatment in teeth with fully developed roots performed before transplantation.^{13,14}

2. Extraction of the impacted canine, points to consider

- Extraction of the labially erupting and crowded canine is contraindicated because such an extraction may complicate and compromise the orthodontic treatment results including the ability to provide the patient with a functional occlusion although it may seem that it improves esthetics.

It might be a workable option if it is ankylosed and cannot be transplanted or if it is undergoing external or internal root resorption or if its root is severely dilacerated or if the impaction is severe (e.g., the canine is lodged between the roots of the central and lateral incisors and orthodontic movement will jeopardize these teeth) or if the occlusion is acceptable, with the

first premolar in the position of the canine and with an otherwise functional occlusion with well-aligned teeth or if there are pathologic changes (e.g., cystic formation, infection) or when the patient does not desire orthodontic treatment.⁵

3. Surgical exposure of the canine and orthodontic treatment to bring the tooth into the line of occlusion

This is obviously the most desirable approach⁵, indications of this approach include well-motivated patient, well-cared-for dentition (good oral hygiene), favorable canine position or space available (or can be created).¹³

Management of the palatally impacted canine

The two most commonly used methods are:

- Surgical exposure allowing natural eruption⁵; Timely uncovering of impacted canine⁶, this method is most useful when the canine has a correct axial inclination and does not need to be uprighted during its eruption⁵, it also prevents the formation of a cyst, periodontal defects, and resorption of the adjacent teeth as well.⁶

It seems appropriate to uncover palatally impacted canines early, during the mixed dentition, so that they can erupt autonomously, without orthodontic intervention, until the crown has erupted to the level of the occlusal plane. At that time, it can be moved more efficiently into the dental arch. By treating palatally impacted canines in this manner, the overall treatment time for the patient is reduced, and the periodontal and esthetic results are superior compared with other methods for exposing palatally impacted canines.¹¹

- Surgical exposure with placement of an auxiliary attachment, such an auxiliary can be either directly bonded to enamel or indirectly attached to a cemented band or crown.

Orthodontic forces are subsequently applied to the attachment to move the impacted tooth.

Kohavi et al further suggested that light movements (e.g., tipping) cause significantly less bone loss than heavy movement (e.g., torque) during the traction of the impacted tooth.⁵

Complications of surgical procedures

Treating unerupted canines can present problems of devitalization, ankylosis, external root resorption, injury to adjacent teeth, and the need for re-exposure. Additionally, marginal bone loss, gingival recession, and sensitivity problems can occur. These effects result in prolonged treatment time, esthetic deformities, and often the loss of teeth. Most of these problems can be prevented with proper management of periodontal

tissues and timing of care.

Management of labially impacted canines

Labially impacted teeth with a favorable vertical position may be treated initially by surgical exposure without the application of a traction force. In younger patients the tooth will erupt on its own after surgical exposure, whereas in older patients traction is almost always indicated.

Before a labially impacted canine is exposed, careful consideration should be given to creation of sufficient space to allow for the canine to be positioned in the arch. The created space will also provide an adequate zone of attached gingiva that can act as a donor site for a partial-thickness apically or laterally repositioned flap.

Techniques for uncovering a labially impacted maxillary canine

- Excisional uncovering. (Fig 3)
- Apically positioned flap. (Fig 4)
- Closed eruption techniques.

Factors to consider in the orthodontic & surgical treatments

1) If the canine crown was uncovered with a closed-eruption technique, the orthodontist should select mechanics that erupt the tooth into the center of the alveolar ridge to produce normal gingival mechanics over the unerupted tooth, he should avoid mechanics that draw the tooth labially, which could produce a bony dehiscence and accelerated migration of the labial gingival margin, resulting in labial recession.

2) When the canine crown is displaced mesially and lies over the root of the permanent lateral incisor (Fig 3), an apically positioned flap is the appropriate surgical uncovering technique. Exposure of the crown facilitates attachment of an elastomeric chain (Fig 3) directed toward the center of the edentulous alveolar ridge to gradually guide the canine crown into the dental arch.

3) Whether orthodontic alignment is feasible or not & the prognosis of the palatally impacted canine depend upon the 3 D position of the unerupted canine:

- Height: the higher a canine is positioned relative to the occlusal plane the poorer is the prognosis, in addition, the access for surgical exposure will be more restricted. If the crown tip is at or above the apical 1/3 of the incisor roots, orthodontic alignment will be very difficult.
- Anteroposterior position: the nearer the canine crown is to the midline the more difficult the alignment will be, most operators regard canines, which are more

than halfway across the upper central incisor, to be outside the limits of orthodontics.

- Position of apex: the further away the canine apex is from normal, the poorer is the prognosis for successful alignment, if its distal to the second premolar, other options should be considered.

In general, horizontally impacted or ankylosed canines are the most difficult to manage and have the poorest prognosis. Some of these teeth may have to be extracted.⁵

REFERENCES

- 1 Preda L, La Fianza A, Di Maggio EM, Dore R, Schifino MR, Campani R, et al. The use of spiral computed tomography in the localization of impacted maxillary canines. *Dentomaxillofac Radiol* 1997;26:236-41.
- 2 Patrick F, Mcsherry B.A. The ectopic maxillary canine: a review. *British journal of orthodontics* 1998;25:209-16.
- 3 Mason C, Papadakou P, Roberts GJ. The radiographic localization of impacted canines: a comparison of methods. *Eur J Orthod* 2003;23:25-34.
- 4 Enrique Fernndez, Luis Alberto Bravo, and Manuel Canteras. Eruption of the permanent upper canine: A radiologic study. *Am J Orthod Dentofacial Orthop* 1998;113:414-20.
- 5 Samir E. Bishara, Impacted maxillary canines: A review. *Am J Orthod Dentofacial Orthop* 1992;101:159-71.
- 6 Peter Ngan, Robert Hornbrook, and Bryan Weaver. Early Timely Management of Ectopically Erupting Maxillary Canines. *Semin Orthod* 2005 11:152-63.
- 7 Kazem Al-Nimri and Tareq Gharaibeh. Space conditions and dental and occlusal features in patients with palatally impacted maxillary canines: an aetiological study. *European Journal of Orthodontics* 2005;27:461-65
- 8 Stella Chaushu, Shaltiel Sharabi, and Adrian Becker. Dental morphologic characteristics of normal versus delayed developing dentitions with palatally displaced canines. *Am J Orthod Dentofacial Orthop*.2002;121:339-46.
- 9 Stanley G Jacobs, Localization of the unerupted maxillary canine: How to and when to. *Am J Orthod Dentofacial Orthop* 1999;115:314-22.
- 10 Ericson S & Kurol J, Early treatment of palatally erupting maxillary canines by extraction of the primary canines, *Eur J Orthod* 1988;10:283-95.
- 11 Vincent G. Kokich, Surgical and orthodontic management of impacted maxillary canines, *Am J Orthod Dentofacial Orthop* 2004;126:278-83.
- 12 Donald J Burden, Brian H Mullally and Stephen N Robinson, Palatally ectopic canines: Closed eruption versus open eruption, *Am J Orthod Dentofacial Orthop* 1999;115:634-39.
- 13 Laura Mitchell, Nigel E. Carter & Bridget Doubleday, An introduction to orthodontics, 2001, 2nd edition, Oxford university press.
- 14 Effie Ioannidou, George P. Makris, Farmington, Conn, and Thessaloniki, Twelve-year follow-up of an autogenous mandibular canine transplant, *Oral Surg Oral Med Oral Pathol Oral Radiol Endod* 2003;96:582-90.
- 15 Giliana Zuccati, Jamilè Ghobadlu, Michele Nieri and Carlo Clausera, Factors associated with the duration of forced eruption of impacted maxillary canines: A retrospective study, *Am J Orthod Dentofacial Orthop* 2006;130:349-56.