

## A COMPARATIVE STUDY BETWEEN TWO MOLAR DISTALIZATION APPLIANCES

\*ABIDA IJAZ, BDS, D. Orth, MCPS, MS

### ABSTRACT

*Class II malocclusion with moderate space deficiency in the maxillary arch and a relatively well-aligned mandibular dental arch can be treated in many ways. One possibility to treat without extraction is to distalize the maxillary first molars to a class I molar relationship in order to gain space in the lateral segments, for retraction of cuspids and anterior teeth. The aim of this study was to compare the clinical dental effects of these two different molar distalization devices, involving 29 patients having class II malocclusion with low angle or normal angle. The Intra-oral Bodily Distalizer (I.B.M.D), which is a fixed appliance that consisted of two pre-activated molar distalization springs bent in TMA wire 0.032 x 0.032 inch and a modified Nance to maintain anchorage, was used in 14 patients. The Acrylic Cervical Occipital Anchorage (A.C.C.O) appliance being a combination of fixed and removable appliance consisting of an acrylic plate with 2 finger springs and a modified labial section-containing groove for the anterior elastic as well as cervical head gear was given in 15 patients. The I.B.M.D and A.C.C.O were used for the mean period of 7.2 months and 11 months respectively. Measurements were made from the lateral cephalogram tracings before and after molar distalization. The results showed that with I.B.M.D maxillary first molar distalized bodily on an average of 4.5 mm and the mean anchorage loss was 4.75 mm. With A.C.C.O mean distal movement of the maxillary first molar was 4.38 mm with mesial tip of 3.03 degree. However, anchorage loss with A.C.C.O appliance was less being 2.11 mm on an average due to the use of the headgear. In I.B.M.D the distalization spring being composed of square sectioned TMA wire distalized the maxillary first molar bodily without any rotation. While with A.C.C.O appliance tipping was seen. However in the maxilla the use of head gear may be effective for orthopedic purpose. Moreover the I.B.M.D. appliance was not patient dependent whereas for A.C.C.O. patient's compliance was found to be a must.*

**Key words:** Molar distalization, Palatal distalizer, Bodily distal movement, Comparison.

### INTRODUCTION

Mild class II malocclusion with moderate space deficiency can be treated orthodontically either with or without extraction of teeth. Treating such a mal occlusion with extraction of teeth is possible, but in such cases opening the bite, particularly in excessive overbite may become a problem. In non-extraction treatment, especially where the mandibular dental arch is well aligned, such a mal occlusion can be treated in many ways.

One way to treat is merely by the use of extra oral force, while another approach of treatment is by the combination of fixed and removable appliances in which mass distal movement of the buccal segments can be attained to get class I molar relationship. Still another and most recent modality of treatment is only by means of intraoral mechanics, using fixed appliances, particularly in dental class II mal occlusions where skeletal effect is not needed. The mechanics being fixed is an effective and reliable method of molar distalization

---

\* Assistant Professor of Orthodontics/Head Department of Dentistry, The Children's Hospital and The Institute of Child Health Lahore. [E-mail: abida\\_ijaz@hotmail.com](mailto:abida_ijaz@hotmail.com)

rendering minimal dependence on patient's compliance.

Extra oral force is applied by means of head gear, that was originally designed by Norman William Kinsley<sup>1</sup> in 1875 as an occipital anchorage and since then publications appeared from time to time.

Angle<sup>2</sup> emphasized the great value of the occipital anchored force by the treatment of cases with extreme maxillary protrusion. Robert Murray Ricketts<sup>3</sup> preferred cervical head gear rather than high pull, as it increases sella gnathion length where as the high pull force does not.

Other modality of treatment is a combination of fixed and removable appliances. Cetlin<sup>4</sup> combined extra oral force (head gear) part time with intra oral force (removable appliance) full time, to prevent tipping of the maxillary molars. David W. Warren<sup>5</sup> presented two case reports of difficult class II mal occlusions that were successfully treated, with Dr. Herbert Margolis A.C.C.O appliance (A.C.C.O) is an acronym for Acrylic Cervical Occipital Anchorage. Telling history of the A.C.C.O appliance, Berstien<sup>6</sup> says that Dr. Herbert Margolis first devised this appliance to "harness growth", that is the entire maxilla was to be restrained while the mandible was allowed to express its growth potential. Then, realizing stability and favorable force application of this appliance, he added various finger spring auxiliaries for distal tooth movement. Through the years further modifications in the design and applications have been made. Jerome L. Blaffer<sup>7</sup> wrote an article in which he mentioned complications arising from the use of simple Margolis A.C.C.O and their remedies.

The third and the most recent modality of treating such a mal occlusion is by using intra oral fixed mechanics only. The intra oral mechanics has an advantage of being independent of the patient's co-operation. Several methods have been devised from time to time, with increasing tendency towards non-extraction treatment. D S. Muse, RD Mitchell<sup>8</sup> carried out a study to determine the magnitude and direction of the maxillary and mandibular first molar and incisor changes, during class II molar correction using Wilson arches.

Richard D. Jones<sup>9</sup> produced distal movement of the molar to class I relationship with an open coil jig, using

an open coil nickel titanium spring to deliver 70 — 75g of force, over a compression range of 1-5mm to the molars. Locatelli<sup>10</sup> presented the use of super elastic nickel titanium wire deflected gingivally into the buccal fold. This method was reported to be comparable with magnets and super elastic Ni-Ti coils. Kuniaki Miyakojima<sup>11</sup> presented distalization with Driftodontics, using preactivated distal extension arm of the lingual arch.

The magnetic forces and nickel titanium coil springs have also been used in molar distalization techniques. In two different studies. Gianelly<sup>12</sup>, achieved effective molar distalization using a modified Nance with repelling magnets. Bondemark and Kurol<sup>13</sup> reported effective molar distalization together with distobuccal rotation.

Open coil springs are commonly used in orthodontics. In order to obtain an optimum force, open coil spring had to be compressed by about a third of its original length, producing a force of 270 to 540g. F. Miura, M. Mogi<sup>14</sup>, compared the mechanical properties of Japanese nickel titanium and stainless steel coil springs in both closed and open types. They found that Japanese nickel titanium coil springs exhibited superior spring back and super elastic properties. AA Gianelly, J. Bednar, VS Dietz<sup>15</sup>, obtained an average of 1 — 1.5 mm molar distalization in one month by 8 — 10 mm activation of super elastic nickel titanium coil springs. N. Erverdi, O. Koyuturk<sup>16</sup> conducted a comparative study between two intra oral molar distalization devices given in the same patient simultaneously. Magnetic devices were applied to the upper right first molars that produced 225 g of repelling force, when the magnets were in tight contact. On the left side, nickel titanium open coil springs size 0.014 x 0.037 inch were used with appropriate length producing 225 g of force. On comparison, distal movement attained with the coil spring was found to be 1.6 mm more than that with the magnets. M. A Darendeliler<sup>17</sup> presented a review and indicated that the use of magnets for orthodontic tooth movements is currently rather limited. Magnets remain too bulky and hard to manufacture for required design to be used as full arch appliance system.

The most recent approach for molar distalization is the lingual distalizer system. Aldo Carano<sup>18</sup> presented two case reports illustrating bodily distalization of the

maxillary molars, without loss of anchorage, using lingual distalizing device. The lingual distalizer had an added advantage of being esthetic and easy to convert into a passive Nance, holding the distalized molars in new position. The rate of distalization with the lingual distalizer is reported to equal the magnets or the Jones jig, but neither tipping nor rotation was observed. Tracy J.Reiner<sup>19</sup> conducted a study on 12 patients to see the effect of modified Nance appliance for unilateral molar distalization. The distal movement attained with this appliance was comparable to that produced by Gianelly<sup>12</sup> using magnets and modified Nance.

J.Gosh, R.Nanda<sup>20</sup> conducted a study to determine the effects of the pendulum appliance on distalization of maxillary molars and the reciprocal effects on the premolars and maxillary incisors. The study showed that the pendulum appliance is an effective and reliable method for distalizing maxillary molars, provided the anchor unit is adequately reinforced. A.Fortini, M lupoli, M.Parri<sup>21</sup> conducted a study on 62 class II patients with First Class Appliance for rapid molar distalization. The study concluded that this appliance produced rapid distalization of the maxillary first and second molars without anterior anchorage loss or changes in vertical dimensions. A Keles, K. Sayinsuv<sup>22</sup> conducted a study on 15 patients to see the effects of Intra Oral Molar Bodily Distalizer on maxillary first molars. The study concluded that the appliance achieved bodily distal movement of maxillary first molars and did not require headgear wear for uprighting of the distalized first molars.

Under the guidance of this literature review, this comparative study was conducted between two different types of appliances, one being a combination of removable plate and head gear (Cetlin mechanics), that is Acrylic Cervical Occipital (A.C.C.O), and the other one a newly introduced fixed Intra Oral Bodily Molar Distalizer (I.B.M.D). The aim of this study was to make a comparison between the clinical dental effects of these two devices, through cephalometric methods.

## **MATERIALS AND METHODS**

In this study 29 patients comprising 13 boys and 16 girls were included. The number of patients wearing I.B.M.D appliance was 14; out of them were 6 boys and 8 girls. The mean age at the start of the treatment was 12.6 years for males, and 14 years for females. The total

mean age for the patients was 13.42, ranging from 11 to 15 years. The A.C.C.O appliance was given to 15 patients including 7 boys and 8 girls. The mean age was 13.85 years for males and 13.37 years for females. The total mean age for this group was 13.68, with a range from 12 to 15 years.

The patients selection was based on the following criteria:

1. Class II molar relationships.
2. All patients were in permanent dentition.
3. Maxillary second molars in occlusion.
4. Well aligned mandibular dental arch.
5. Sagittally directed or normal growth pattern.
6. A minimum of 2 mm over bite.

Intra oral photographs, lateral head films, and the dental casts were obtained at the start of the treatment and at the end of molar distalization.

## **Cephalometric Analysis**

To analyze parameters other than dental changes related to the maxilla, conventional lateral cephalometric radiographs were taken before and after the cementation of the appliance. However for analysis of the parameters related to the maxillary dental changes, we developed a new method. Most of the time it is difficult to identify the inclination of the right and left molars and premolars on cephalometric radiographs because of the superimposition of the right side to the left side. We used 0.032 inch size wire markers. These markers were oriented vertically and retained in the acrylic caps, which were made for maxillary first molars, first premolars and right central incisor. On the right side the tip of the wires were bent distally and on the left side the tip of the wires were bent mesially. On the right side the markers were oriented vertically from the distal and on the left side the wires were oriented vertically from the mesial in order to prevent superimposition of these markers on the cephalograms (fig 1, 2). The markers were cemented temporarily to the molars, premolars and right central incisor respectively. Lateral cephalometric radiographs were taken and analyzed before and after molar distalization.

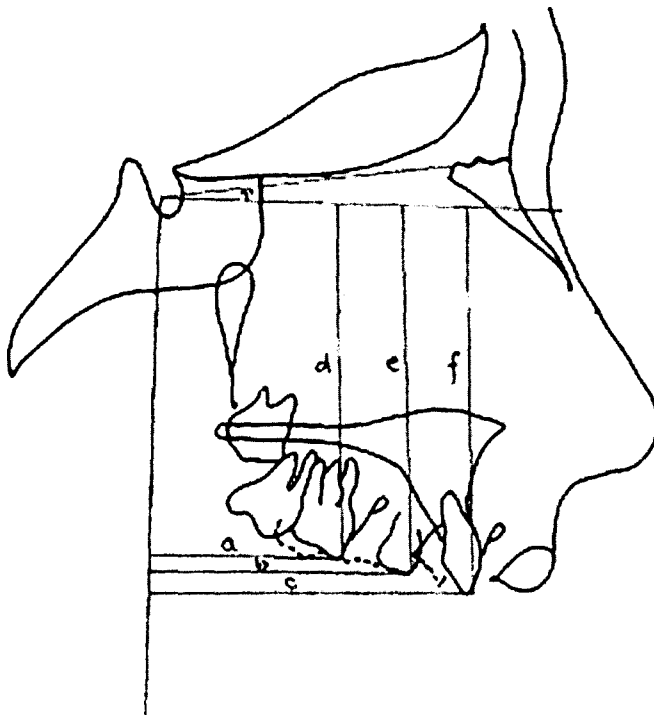


Fig 1. Cephalometric Parameters used for Linear Measurements.

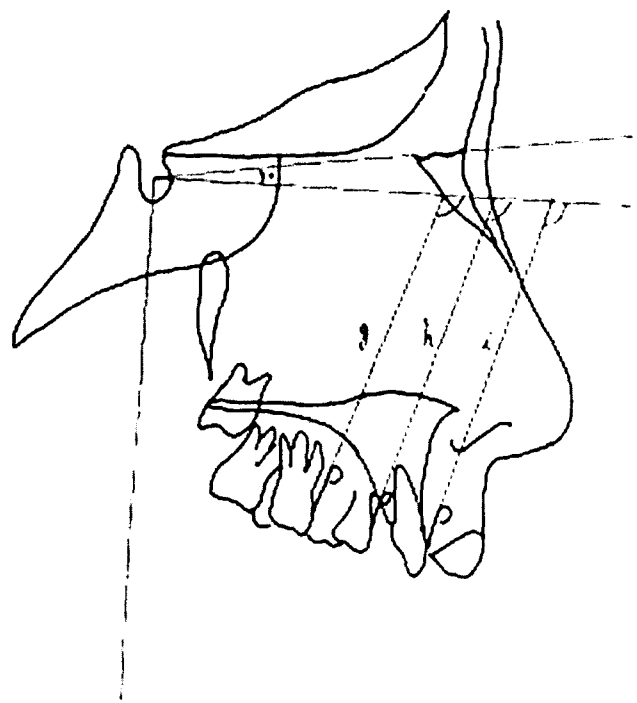


Fig. 2. Cephalometric Parameters used for Angular Measurements.

The reference plane used in the cephalometric analysis was the Sella-Nasion plane. The sella-nasion correction due to posture was made at  $7^\circ$  and a true horizontal and a true vertical were drawn respectively. The Sella was registered and super imposed on to the post treatment lateral head film. A total of fifteen variables were used in the cephalometric analysis (fig 1, 2). The following

- a) Distance from the wire marker on the maxillary first molar to the true vertical.
- b) Distance from the wire marker on the maxillary first premolar to the true vertical.
- c) Distance from the wire marker on the maxillary central incisor to the true vertical.
- d) Distance from the wire marker on the maxillary first molar to the true horizontal.
- e) Distance from the wire marker on the maxillary first premolar to the true horizontal.
- f) Distance from the wire marker on the maxillary central incisor to the true horizontal.

two cephalometric measurements were made in this study

- Linear measurements. The linear measurements were made from the wire markers to the true vertical and true horizontal respectively, (fig 1; table 1).
- Angular measurements. The angular measurements were made at the anterior angle formed by the intersection of the true horizontal and the long axis of the wire marker.
  - g) Angle between the molar marker and the true horizontal.
  - h) Angle between the first premolar marker and the true horizontal.
  - i) Angle between the central incisor and the true horizontal.

## Appliance Construction

### I.B.M.D Appliance

The bands of proper size were fitted on the maxillary first molars and maxillary first premolar teeth. On the palatal surface of the first molar band 0.032x 0.032 inch slot size hinge cap palatal attachments were welded (fig. 3). On the cast, wire segments for first premolars were bent from 1.0 mm stainless steel wire and soldered to premolar bands. For molar distalization

**TABLE 1: LINEAR MEASUREMENT IN MILLIMETRES WITH I.B.M.D & A.C.C.O APPLIANCE. FROM THE TRUE VERTICAL (+) DISTAL MOVEMENT, (-) MESIAL MOVEMENT, AND FROM THE TRUE HORIZONTAL (+) EXTRUSION, (-) INTRUSION.**

|                                 | I.B.M.C                        |                                  | A.C.C.O                        |                                  |
|---------------------------------|--------------------------------|----------------------------------|--------------------------------|----------------------------------|
|                                 | <b>True<br/>Verti-<br/>cal</b> | <b>True<br/>Hori-<br/>zontal</b> | <b>True<br/>Verti-<br/>cal</b> | <b>True<br/>Hori-<br/>zontal</b> |
| Maxillary<br>First<br>Molar     | 4.5                            | 0.76                             | 4.38                           | 2.58                             |
| Maxillary<br>First<br>Premolar  | -4.75                          | 3.924                            | -2.11                          | 1.895                            |
| Maxillary<br>Central<br>Incisor | -3.85                          | 1.64                             | -2.2                           | 0.96                             |

0.032 x 0.032 inch size TMA springs with two helices (each 2.5 mm in diameter) were designed. The first helix was bent 1mm distal to the hinge cap attachment, where as the second helix was placed in the inter space between first and second molar tooth and 1-1/2 cm away from the gingival margin, in the apical region. Before Nance fabrication, a continuous torque like bend was placed in the uprighting section of the spring towards the mid line. The purpose of this bend was to make the uprighting section passive in the palatal hinge cap attachment slot (0.032 x 0.032 inch slot size).


The Nance covered the palatal surface of incisors, making an anterior bite plane to provide 2mm occlusal clearance in the buccal segments.

Posteriorly it extended as far backward as the first molar.

Increasing acrylic part in the Nance rendered it more rigid anchorage reinforcement device. At the time of insertion, antirotation bend was placed in the

**TABLE 2: ANGULAR MEASUREMENT WITH I.B.M.D AND A.C.C.O APPLIANCE (+) DISTAL TIP (-) MESIAL TIP**

|                           | <b>I.B.M.D</b> | <b>A.C.C.O</b> |
|---------------------------|----------------|----------------|
| Maxillary First Molar     | 0.36           | -3.03          |
| Maxillary First Premolar  | 2.99           | -5.11          |
| Maxillary Central Incisor | -5.32          | -5.13          |

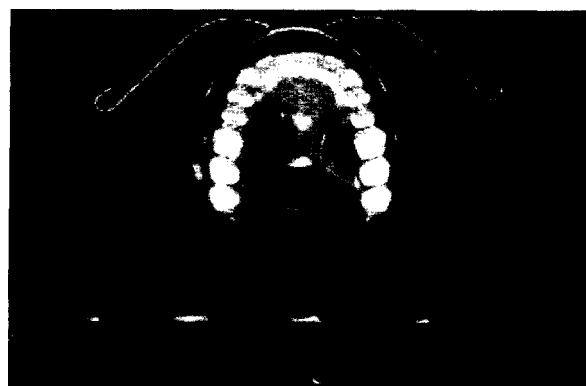


**Fig 3. The Intra Oral Bodily Molar Distalization Appliance (I.B.M.D). Molar Distalization Springs in Passive Position**

middle of the distalizing section. For insertion the distalizer was cemented to the first premolars without the spring engaged. After cementation, the hinge caps on the molar bands were opened. Activations of the springs were accomplished by pulling mesially with a pair of Wiengart pliers and then seated into the slot of the palatal hinge cap attachments and the caps were closed. 230 grams of distal force was applied to the first molars. The patient was recalled every three weeks to see progress, and the spring was reactivated when needed.

#### **A.C.C.O Appliance**

The cast was prepared in stone with bands on the maxillary first molars. On the cast, the anterior wire segment was made from 0.022x 0.028inch stainless steel wire (fig 4). Adam's clasps were designed in 0.7



**Fig 4. The Acrylic Cervical Occipital Anchorage Appliance (A.C.C.O). The Appliance on insertion with face bow and anterior elastic along with cervical pull head gear.**

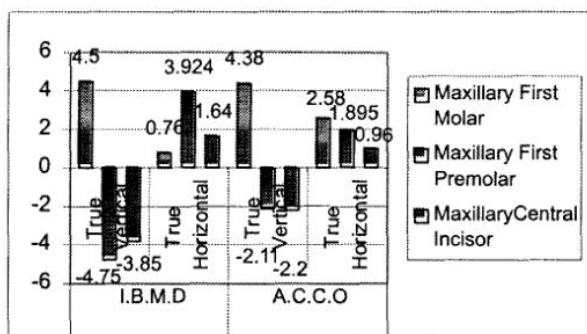


Fig 5. Comparison of Linear Measurement with I.B.M.D & A.C.C.O Appliance.

mm stainless steel wire for the first premolars for retention, as these teeth served as anchor teeth in the appliance.

For molar distalization, two cantilever springs, each with one helix (2.5 mm in diameter) were fabricated from 0.8 mm stainless steel. The helix of the spring was placed in the inter space between upper first and second molar, about 1-1/2 cm away from the gingival margin (apical part). The span distal to the active arm of the spring was covered with 1mm thick wax, from distal of the spring backwards to the distal of the second molar, and from the gingival margin extending medially to the end of the helix to facilitate distal movement of the spring. The acrylic was extended anteriorly on to the labial surface of the incisors till cervical margin, embedding the wire loops in to it.

The incisal edges of the appliance were exposed and a groove about 1mm deep was drilled on the labial section of the appliance at the mid crown length level for the anterior elastic (fig 4). For insertion, molar bands were cemented to the first molars and the appliance was tried in the mouth for fit. The distalizing spring was pre-activated and the appliance was inserted. After insertion, the proper size face bow was fabricated. A 0.9 mm stainless steel wire bent in the form of hook was then soldered to the inner bow in the canine region, for anterior elastic. The outer bow was bent upwards so that it passed through the apex of the upper first molar and terminated in the furcation point to receive the neck strap. The force applied on each side was about 300 grams that was measured with Gram's gauge. Anterior elastic was applied across the hooks of the inner bow that passed through the anterior groove,

and exerted 100 grams of force. The distalizing spring was activated after every three weeks by 1.0 to 1.5 mm that generated distal tipping force to the crowns of the maxillary first molars. Action of the spring was to tip the crown distally and that of the cervical head gear was to upright the root. The combined action of the plate and cervical head gear resulted in bodily distalization of the maxillary first molar tooth.

## RESULTS

Cephalometric results of the study are given in table I, 2 with their graphic representation in figure 5, 6. With I.B.M.D appliance the maxillary first molars were distalized bodily on an average of 4.5mm. Maxillary molar extrusion was observed but it was negligible (0.76mm). Class I molar relationship was achieved in all cases in an average duration of 7.5 months. The maxillary first premolars mesialized an average of 4.75mm, extruded 3.924mm and tipped distally 2.99°. The maxillary incisors proclined 5.32° protruded 3.85mm and extruded 1.64 mm on average.

With A.C.C.O appliance, the maxillary first molars distalized an average of 4.38 mm, showed mesial tipping of 3.03°angle and 2.58 mm extrusion was observed. Class I molar relationship was achieved in all cases in an average duration of 11 months. The maxillary first premolars mesialized 2.11mm, extruded 1.895 mm and tipped (rotated buccomesially) by 5.11°angle. The maxillary incisors proclined on an average of 5.13° and their protrusion observed was 2.2 mm. There was 0.96 mm of incisor extrusion found with ACCO appliance.

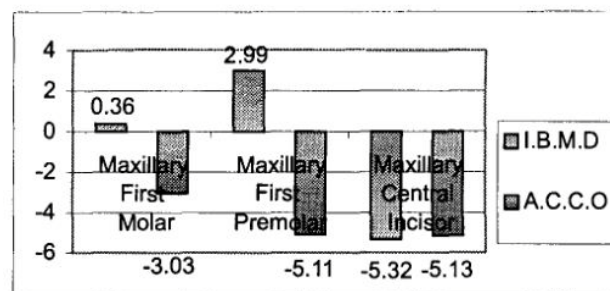


Fig 6. Comparison of Angular Measurement with IB.M.D and A.C.C.O Appliance (+) Distal Tip, (-) Mesial Tip

## DISCUSSION

With I.B.M.D appliance the results showed that maxillary molars distalized bodily without any rotation (table 1, 2 fig.5, 6). Looking at the dental effects of this newly introduced appliance, in all cases class II molar relationship was corrected and class I molar relationship was achieved by means of 4.5 mm bodily maxillary molar distalization in an average duration of 7.5 months. Distal tipping was negligible (table 2) and extrusion was not significant (table 1) being 0.76mm. The dental changes related to the first premolars showed that for every millimeter of distal molar movement, the premolars moved mesially by 1.05mm. This would explain that bodily molar distalization requires more anchorage reinforcement. The dental effects on the maxillary incisors showed their protrusion on an average by 3.85mm (table 1, fig.5) and proclination on an average by  $5.32^\circ$  (table 2, fig.6). However, these teeth extruded on an average by 1.64 mm (table 1, fig.5).

After molar distalization, during the stabilization period with Nance button for two months, premolars drifted distally and the overjet was reduced simultaneously without any orthodontic therapy. With the removal of the distalizer, mesially directed force on premolars and incisors was eliminated and then the anchorage unit relapsed distally<sup>22</sup>.

With A.C.C.O appliance, the study revealed that class II molar relationship was corrected to class I molar relationship in a period of 11 months on an average. 15 patients were included in the treatment. The dental changes related to the maxillary first molars showed a distal movement of 4.38mm on an average (table 1, fig.5). Patient's compliance for head gear wear was found to be a must. However these teeth showed a mesial tip of  $3.03^\circ$  angle (table, fig 6) that explains more of the head gear effect and face bow design than that of the distalizing spring. The mean extrusion observed was 2.58mm. Looking at the dental effects of this appliance on the maxillary first premolars, for every millimetre of molar distalization, the anchorage loss was 0.48mm. This comparative decrease in the anchorage loss was due to anchorage reinforcement means incorporated into the appliance such as the head gear, anterior elastic and anterior looped wire segment. The dental effects of this appliance on the maxillary incisors revealed an average proclination of  $5.13^\circ$  (table 2, fig 6) and their protrusion observed was

2.2mm (table 1, fig 5). However these teeth extruded 0.96mm on an average (table 1, fig 5).

If we consider the efficacy of the I.B.M.D, this newly introduced device did not depend on patient's compliance and did not require head gear for root uprighting unlike other intraoral molar distalization mechanics<sup>12,13,14,15,16</sup>. The Nance was constructed wide enough to cover the anterior aspect of the palate and the cinguli of the incisor teeth<sup>12</sup>. The purpose was to reinforce the anchorage. According to Joy Deep Gosh<sup>20</sup> in pendulum appliance, anchorage loss could possibly be reduced if the anchor unit was adequately reinforced by full palatal coverage. In the appliance design, maxillary first premolars were banded and connected to the acrylic plate as described by Gianelly<sup>12</sup>

The acrylic button had an anterior bite plane, which was effective in deep bite correction and also facilitated molar distalization by disoccluding the buccal segments.

For distalization of molars 0.032 x 0.032 inch TMA distalizing springs were used (fig 3). The purpose of using square sectioned springs for molar distalization was to have a better transverse control<sup>22</sup>. The springs consisted of two components. The distalizer section and the uprighting section. The distalizer section applied crown tipping, and the uprighting section applied root movement, thereby inducing an uprighting effect on the molar root, while the crown was being distalized because of 8-10 mm preactivation built in to the spring design. Based on the elastic properties of the TMA, the spring's distalizer section was activated by pulling the uprighting section mesially without plastic deformation to be engaged into the hinge cap attachment. Unlike pendulum appliance<sup>20</sup> the springs moved the maxillary molars distally, towards the direction where the springs were in their inactive stage<sup>22</sup> (fig 3).

In this appliance, approximately 230 grams of force was applied to the first molars. In the literatures, the forces ranged from 75gm to 230gm.<sup>9,10,11,12,13,14,15,16,18,19,20,21,22</sup> Distal tipping and extrusion of molars with I.B.M.D appliance were not significant<sup>22</sup>.

Maxillary molars were distalized bodily<sup>21,22</sup>, unlike pendulum appliance of Nanda<sup>20</sup> and Gianelly mechanics<sup>12, 15</sup> and Bondemark and Kurol appliance<sup>13</sup>, where distal tipping was reported respectively and the use of head gear was recommended to stabilize the distalized molars.

## I.B.M.D versus A.C.C.O Appliance

If we compare the dental effects produced by these appliances, with I.B.M.D the maxillary molars were distalized bodily without any rotation and distal tipping was not significant. Where as with A.C.C.O appliance, the maxillary first molars tipped mesially by 3.03° angle, which shows that, the effect of head gear was induced more than that of the distalizing springs. Extrusion of the molars seen with I.B.M.D appliance was negligible being 0.76mm and with A.C.C.O the molars extruded on an average by 2.58mm. This extrusion was due to the effect of cervical head gear used and the face bow design. Anchorage loss seen in case of I.B.M.D was more than that of A.C.C.O.

With I.B.M.D for every millimeter of distal molar movement, the premolars moved mesially by 1.05mm and in A.C.C.O, anchorage loss per millimeter distalization of the molar was about 0.5mm. As mentioned before, this decrease in the mesial movement of premolars was the effect of head gear and the face bow design, where as in I.B.M.D increased anchorage loss demands anchorage reinforcement. Moreover, the maxillary first premolars with I.B.M.D showed a distal tip which was the reaction of the force applied by the molar distalizing springs.

The anterior bite plane was provided in both appliances that disoccluded the posterior teeth and facilitated molar distalization as well as eruption in the lower posterior segments.

## CONCLUSIONS

On the basis of results of this study conducted on 29 patients, the following conclusions may be drawn:

1. I.B.M.D is an effective appliance for the bodily distalization of molars without using any extra oral appliance or other intra oral mechanics.
2. The treatment time can be minimized using IBMD appliance with maximum efficacy
3. In the A.C.C.O appliance, extrusion of the molars as a result of cervical pull head gear and upward face bow design, suggested alteration in the design of the outer bow. Perhaps by lowering it down may decrease the amount of extrusion. However on the maxilla in order to correct class II skeletal pattern, the use of head gear could be effective to obtain orthopedic effect.

## ACKNOWLEDGMENT

I am thankful to Dr Ahmed Keles, Associate Prof of Orthodontics at Marmara University Istanbul, Turkey for his guidance throughout this study. Thanks are also due to my colleagues who helped me in attaining material for the study.

## REFERENCES

1. Kinsley N. W. Oral Deformities: Treatise on oral deformities as a branch of mechanical surgery, New York, Appleton-century Co., 1880.
2. Angle E. H. Treatment of malocclusion of teeth, Ed 7, Philadelphia, 1907, SS white Manufacturing Company.
3. Ricketts RM, Bench R W, Gugino CF, Hilger JJ, Schulhof RJ. Orthopaedics in Bioprogressive Therapy. Bioprogressive Therapy, 1980. Section I: Part 5:71-92.
4. Cetlin NM, Ten Hoove A. Non-Extraction treatment. J. Clinical Orthod 1993; 17:396-413.
5. Warren DW. Clinical Applications of the A.C.C.O Appliance Part 1. AJO 1992; 101:101-111.
6. Bernstein L. Treatment of Class 2 Division 1 Maximum Anchorage Cases JCO 1970; 4: 374-383.
7. Blaffer JL. Trouble shooting the A.C.C.O. JCO 1970; 4: 440-461.
8. Muse DS, Mitchell RD. Molar and Incisor Changes with Wilson Rapid Molar Distalization. AJO 1993; 104:556--565.
9. Jones RD, White JM. Rapid Class 2 Molar Correction with an Open Coil Jig. JCO. 1992; 26: 661-664.
10. Locatelli R, Gianelly AA. Molar Distalization with Super Elastic Niti Wire. JCO. 1992; 26:277-278.
11. Miyakojima K, Nakamura S. Distalization with Driftodontics. JCO 1994; 28:393-394.
12. Gianelly AA, Bonds PW and Johnson W.M. Distalization of Molar with Repelling Magnets. JCO. 1998; 22: 40-44.
13. Bondemark, Kurol J. Distalization of Maxillary First and Second Molars Simultaneously With Repelling Magnets. Eur.J. Orthod 1992; 14:246-272.
14. Miura F, Mogi M. The Super Elastic Japanese Niti Alloy Wire for Use in Orthodontics. AJO 1988; 94:89-96.
15. Gianelly A.A. Bednar J and DietzVS. Japanese Niti Coil Used to Move Molars Distally. AJO 1991; 99:564-566.
16. Erverdi N, Koyuturk O, Niti Coil Springs and Repelling Magnets. British J. Orthod 1997; 24:147-53.
17. Darendeliler M A. Clinical Application of Magnets in Orthodontics and Biological Implications. A review. European J. Orthod 1997; 19:431-442.
18. Carano A, Sciciliani G. The Lingual Distalizer System. European J. Orthod 1996; 18:445-448.
19. Reiner TJ. Modified Nance Appliance for Unilateral Molar Distalization. JCO 1992; 26:402-404.
20. Ghosh J, Nanda R. Evaluation of an intraoral Maxillary molar distalization technique. AJO 1996; 110:672-6
21. Fortini A, Lupoli M, Parri M, The First Class Appliance for Rapid Molar Distalization.. JCO 1999; 33:322-328
22. Keles A, Sayinsu K. A New Approach in Maxillary Molar Distalization: Intra Oral Bodily Molar Distalizer .Am J Orthod Dentofacial Orthop 2000; 117:39-48