

FREQUENCY OF SECOND CANAL IN MANDIBULAR LATERAL INCISORS (IN-VITRO)

¹MUHAMMAD ARIF SHAIKH, BDS, MSc

²FEROZE ALI KALHORO, BDS, FCPS

³LAILA SANGI, BDS, MSc

ABSTRACT

Objective of the study was to determine the frequency of second canal in extracted mandibular lateral incisors. It was observational study and was conducted in the Dental Outpatient's Department of Liaquat University of Medical and Health Sciences Hospital, Hyderabad / Jamshoro from 1st January 2010 to 31st March 2010.

This study included 100 extracted permanent mandibular lateral incisors. These extracted teeth were stored in 10% formalin until access preparation was made. Pulp chamber was accessed using round bur and then irrigated with sodium hypochlorite till it is clearly visible. Then DG16 endodontic explorer was used for the location and negotiation of second canal after location of main canal. Teeth in which second canal was located, No. 10 K-files were inserted into main canal and second canal. Then two periapical radiographs from the buccolingual and proximal sides were taken for confirmation. Results were then recorded in proforma.

Single canal was found in 61% of permanent mandibular lateral incisors. 39% of permanent mandibular lateral incisors had second canal.

The frequency of second canal in the present study was 39% of permanent mandibular lateral incisors.

Key Words: Access cavity, Mandibular lateral incisors, Root canal, Second canal.

INTRODUCTION

Knowledge of internal anatomy of tooth is an important factor for undergoing a successful endodontic treatment. To prevent unnecessary failures one must have sufficient know how of internal anatomy as well as its possible different morphologic variations.^{1,2} Understanding disparity in tooth anatomy due to racial differences are again a matter of concern for negotiation and management of root canals.^{3,4}

There may be one canal with an ovoid or ribbon-shaped configuration or two canals.⁵ The frequency of two canals in mandibular incisor is reported

approximately 41.4% of all mandibular anteriors.⁶ So the existence of second canal must be suspected.⁶ When there are two canals, the facial canal is easier to locate and is generally straighter than the lingual canal, which is often shielded by a lingual shelf. The lingual aspect of the pulp chamber should be opened adequately to remove the lingual shelf of dentin over the second canal.⁵

Different techniques can be used to study root canal morphology of mandibular lateral incisors including radiographic examination⁷, root sectioning⁸ and staining and clearing techniques.⁹ In the present study, radiographs were taken in both buccolingual and mesiodistal direction (Radiovisiography), as it helps in three dimensional view of an object.

The results of previous studies conducted on prevalence of second canals in mandibular incisors are inconsistent.^{8,10,11} The data of previous reports are largely based on teeth of mainly Caucasoid origin.

¹ Assistant Professor, Department of Operative Dentistry, Institute of Dentistry, Liaquat University of Medical & Health Sciences, Jamshoro, Sindh. Email: dentistshaikh@yahoo.com
Cell Number: 0333-2603050

² Associate Professor, Operative Dentistry
Email: drferoze_76@yahoo.com
Cell Number: 0300-2641705

³ Assistant Professor Operative Dentistry,
Email: laila_sangi@yahoo.com

Received for Publication: January 5, 2014

Accepted: January 20, 2014

Furthermore studies conducted in other populations shows a definite variation based on racial differences especially in the Asian population.^{12,13,14,15,16} There are no local published reports on the root canal anatomy of mandibular lateral incisors. Until now no comprehensive or significant study has been performed which records these variations in the Pakistani population. All the available data which is taught at the undergraduate as well as post-graduate level is obtained mostly from research studies conducted in Europe and North America from Caucasian population. The objective of current study was to determine the frequency of second canal in extracted mandibular lateral incisors in the Hyderabad population. This study will therefore help in performing the root canal treatment with a better understanding of the internal anatomy of the mandibular lateral incisors.

METHODOLOGY

A total number of 100 extracted permanent mandibular lateral incisors were collected from different dental clinics, hospitals and universities within Hyderabad. These extracted teeth were then stored in 10% formalin until use. No information was collected regarding reason for their extraction or the age and gender of the patient. Pulp chamber was accessed using round bur in a high speed hand piece. The pulp chamber was then irrigated with a 2.5% sodium hypochlorite till pulp chamber was made clearly visible. The pulp chamber was then dried with the help of air from the triple syringe. Following the access cavity preparation and location of main canal, the detection and negotiation of second canal was attempted by exploring method with DG16 endodontic explorer under operating light. Teeth in which a second canal was located, No. 10 K-files were inserted into main canal and the second canal. Then two periapical radiographs from the buccolingual and proximal sides (Radiovisiography) were taken for confirmation. Data was then recorded in Proforma.

RESULTS

A total number of 100 extracted permanent mandibular lateral incisors were examined. Out of total sample the frequency of the second canal was determined in 39 (39%) whereas single canal was found in 61 (61%) extracted permanent mandibular lateral incisors. Results are shown in Fig 1.

DISCUSSION

Knowledge of the morphology of the pulp cavity is essential for successful root canal therapy. Mandibular lateral incisors have been reported presenting two canals within a single root.^{6,17} Presence of missed second canal is one of the main reasons for endodontic failure of mandibular incisors. When only one canal is treated

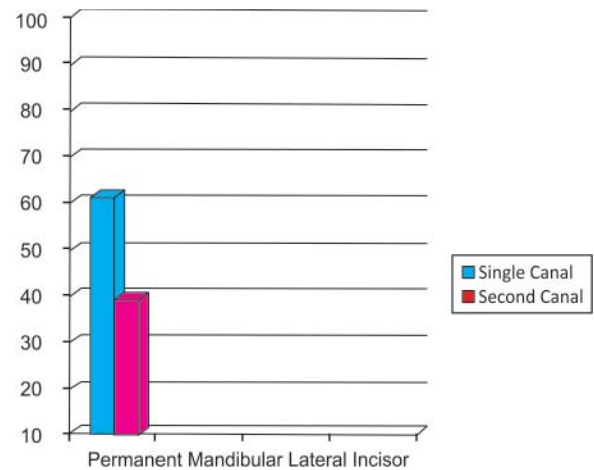


Fig 1: Frequency of second canal in permanent mandibular lateral incisor(%) n=100

the pulp tissue in the second canal is or may eventually become necrotic and can liberate noxious by-products.

If dentists notice that a root canal shows a sudden narrowing or even disappears on the direct periapical exposure, it means that at this the canal divides into two parts. It is recommended in literature that radiographs should be examined from several different angles before to access preparation¹⁸ and dentists must always be on the watch for existence of two canals.⁸

Various techniques have been used to study root canal morphology of mandibular lateral incisors including radiographic examination⁷, root sectioning⁸ and staining and clearing techniques.⁹ All methods used to study root canal morphology may have shortcomings.¹⁹ In the present study, radiographs were taken in both buccolingual and mesiodistal direction (Radiovisiography), as it helps in three dimensional view of an object.

According to various conducted studies of pulp morphology, second canal is found in 11-68% of mandibular incisors.^{8,10,11,20,21,22} Rankine-Wilson & Henry in 1965 reported second canals in 40.5% of mandibular incisors.¹⁷ Vertucci in 1974 examined the root canal morphology of 300 extracted mandibular anterior teeth using clearing technique. Second canal was found in 25% of mandibular lateral incisors.¹¹ Benjamin KA & Dowson J in 1974 studied three hundred sixty four extracted human mandibular incisors radiographically to determine the incidence of two main root canals. Second canal was found in 41.4% of the sample.⁶

Walker in 1988 reported the occurrence of a second canal in the mandibular incisors was infrequent in people of East Asian origin but more frequent in people of European origin.¹⁹ Gomes and others in 1996 found second canal in 35.8% of 53 mandibular lateral incisors.²³ Miyashita and others in 1997 examined 1085 extracted mandibular incisors. Single canal was found

in 85% of the root canals while second canal was found in 15% of total specimens.²⁰

Sert S and others in 2004 investigated the root and canal morphology of 200 mandibular permanent lateral incisors. Second canal was found in 63% of mandibular lateral incisors.¹⁰ In a study conducted by Ezoddini and Tabrizizadeh in 2006, 55.9% of teeth possessed second canal.²⁴ According to results of another study conducted by Al-Qudah and Awawdeh in 2006, the majority of mandibular incisors had a single canal in 73.8% of teeth, second canal was found in 26.2% of teeth.²⁵ One hundred forty three mandibular incisors were treated endodontically. Single canal was found in 70.67% and multiple canals were found in 29.33% of treated mandibular lateral incisors.²⁶

In the present study, single canal was found in 61% of permanent mandibular lateral incisors. Second canal was found in 39% of permanent mandibular lateral incisors. The occurrence of second canal in the current study was within the range of previous reports. In previous studies described above, second canal was found in 11-68% of mandibular incisors.^{8,10,11,20,21,22}

Various studies have been conducted, but the results are inconsistent.^{7,8,10,11,19} These variations in results may be because of differences in study design (in vivo versus ex vivo), technique of canal identification (radiographic examination, sectioning and clearing), racial divergence, classification systems, sample size, ethnic background of tooth sources and patient's age during the time of extraction. It is known that because of the deposition of cementum or dentin, some roots canals would be obliterated by age.²⁷

CONCLUSION

The frequency of second canal in present study was 39 (39%) in permanent mandibular lateral incisors. Single canal was found in 61 (61%) permanent mandibular lateral incisors. The frequency of second canal in the present study was within the range of previous reports.

REFERENCES

- Cohen S, Burns RC. Pathways of the pulp. 8th ed. St Louis: Mosby; 2002: 173-229.
- Ingle JI, Backand LK. Endodontics. 5th ed. Hamilton: BC Decker; 2002: 405-570.
- Sert S, Bayirli GS. Evaluation of the root canal configurations of the mandibular and maxillary permanent teeth by gender in the Turkish population. *J Endod* 2004; 30(6): 391-8.
- Weine FS, Hayami S, Hata G, Toda T. Canal configuration of the mesiobuccal root of the maxillary first molar of a Japanese sub-population. *Int Endod J* 1999; 32: 79-87.
- Mauger MJ, Waite RM, Alexander JB, Schindler WG. Ideal endodontic access in mandibular incisors. *J Endod* 1999; 25(3): 206-7.
- Benjamin KA, Dowson J. Incidence of two root canals in human mandibular incisor teeth. *Oral Surg Oral Med Oral Pathol* 1974; 38(1): 122-6.
- Kaffe I, Kaufman A, Littner MM, Lazarson A. Radiographic study of the root canal system of mandibular anterior teeth. *Int Endod J* 1985; 18(4): 253-9.
- Mauger MJ, Schindler WG, Walker WA. An evaluation of canal morphology at different levels of root resection in mandibular incisors. *J Endod* 1998; 24(9): 607-9.
- Robertson D, Leeb IJ, McKee M, Brewer E. A clearing technique for the study of root canal systems. *J Endod* 1980; 6(1): 421-4.
- Sert S, Aslanalp V, Tanalp J. Investigation of the root canal configurations of mandibular permanent teeth in the Turkish population. *Int Endod J* 2004; 37: 494-9.
- Vertucci FJ. Root canal anatomy of the mandibular anterior teeth. *J Am Dent Assoc* 1974; 89: 369-71.
- Goel NK, Gill KS, Taneja JR. Study of root canals configuration in mandibular first permanent molar. *J Indian Soc Pedod Prev Dent* 1991; 8(1): 12-4.
- Vertucci FJ. Root canal anatomy of the human permanent teeth. *Oral Surg Oral Med Oral Pathol* 1984; 58(5): 589-99.
- Gulabivala K, Opsanon A, Ng YL, Alavi A. Root and canal morphology of Thai mandibular molars. *Int Endod J* 2002; 35(1): 56-62.
- Wasti F, Shearer AC, Wilson NH. Root canal systems of the mandibular and maxillary first permanent molar teeth of south Asian Pakistanis. *Int Endod J* 2001; 34(4): 263-6.
- Skidmore AE, Bjorndal AM. Root canal morphology of the human mandibular first molar. *Oral Surg Oral Med Oral Pathol* 1971; 32(5): 778-84.
- Rankine-Wilson RW, Henry P. The bifurcated root canal in lower anterior teeth. *J Am Dent Assoc* 1965; 70: 1162-5.
- Skidmore AE. The importance of preoperative radiographs and the determination of root canal configuration. *Quintessence Int Dent Dig* 1979; 10(3): 55-61.
- Walker RT. The root canal anatomy of mandibular incisors in a southern Chinese population. *Int Endod J* 1988; 21(3): 218-23.
- Miyashita M, Kasahara E, Yasuda E, Yamamoto A, Sekizawa T. Root canal system of the mandibular incisor. *J Endod* 1997; 23(8): 479-84.
- Kartal N, Yanikoglu FC. Root canal morphology of mandibular incisors. *J Endod* 1992; 18(11): 562-4.
- Madeira MC, Hetem S. Incidence of bifurcations in mandibular incisors. *Oral Surg Oral Med Oral Pathol* 1973; 36(4): 589-91.
- Gomes BP, Rodrigues HH, Tancredo N. The use of a modelling technique to investigate the root canal morphology of mandibular incisors. *Int Endod J* 1996; 29(1): 29-36.
- Ezoddini F, Tabrizizadeh M. Root canal morphology of human mandibular incisors in Yazd province. *Dental Research Journal* 2006; 3(1): 1-3.
- Al-Qudah AA, Awawdeh LA. Root canal morphology of mandibular incisors in a Jordanian population. *Int Endod J* 2006; 39(11): 873-7.
- Xu Q, Liu HY, Ling JQ, Luo DF. Clinical management of mandibular incisors with multiple root canals using dental operating microscope. *Hua Xi Kou Qiang Yi Xue Za Zhi* 2008; 26(5): 522-5.
- Pineda F, Kuttler Y. Mesiodistal and buccolingual roentgenographic investigation of 7,275 root canals. *Oral Surg Oral Med Oral Pathol* 1972; 33(1): 101-10.