

## FREQUENCY OF FOURTH CANAL IN PERMANENT MANDIBULAR FIRST MOLARS

<sup>1</sup>FOZIA RAJPUT, BDS, MSC, FCPS

<sup>2</sup>MUHAMMAD ARIF SHAIKH, BDS, MSc

<sup>3</sup>MOHAMMAD ILYAS SHAIKH, BDS, FCPS

<sup>4</sup>KHAWAR KARIM, BDS

### ABSTRACT

*This study was carried out to investigate the frequency of fourth (distolingual) canal in the permanent mandibular first molars and to determine the effect of modified access cavity preparation for endodontic treatment. It was an observational study. The study was conducted at the Department of Operative Dentistry, Institute of Dentistry, Liaquat University of Medical & Health Sciences, Jamshoro/Hyderabad from September 2009 to February 2010.*

*Two hundred permanent mandibular first molars were selected from male and female patients presenting for endodontic treatment. The method used for exploring the fourth canal was the modified access cavity preparation which involved changing the triangular access cavity shape to a quadrangular shape. The study involved careful selection criteria, pre-operative radiological examination and then triangular access cavity preparation. The number of canals found by triangular access cavity preparation was noted on the proforma before extending the shape to a quadrangular shape and then a thorough exploration of the floor of the pulp chamber was done. Finally, if fourth canal was present, the presence of the fourth canal was confirmed by taking two periapical radiographs at two different angles with 15 # K files in the root canals. The data collected were analyzed using the chi square test.*

*The results showed that fourth canal was found in 36% of permanent mandibular first molars.*

*The effect of modified access cavity preparation was significantly higher ( $P= 0.0001$ ) in cases with a fourth canal than in teeth with three canals ( $P= 0.05$ ). Statistically there was insignificant difference ( $P= 0.7$ ) between the genders for the occurrence of fourth canal.*

*Conclusions: This study demonstrates that there is a greater frequency of fourth canal in the permanent mandibular first molar teeth than previously thought. Also changing the shape of access cavity from a triangular outline to a quadrangular outline facilitates in locating the fourth canal.*

**Key Words:** Mandibular first molar, Access cavity, Distal root, Fourth canal, Distolingual canal.

### INTRODUCTION

Mandibular first molars are often the first permanent teeth to erupt in the oral cavity. Their functions

include mastication, maintenance of the vertical dimension of the face and also the stability of the lower arch. These teeth require endodontic treatment to greater extent compared with other teeth.<sup>1</sup> The knowledge of internal root anatomy is considered as the basic step in the success of endodontics. In addition an accurate diagnosis and a proper preparation of the canalicular system will enhance the clinical outcome. However, undetected supplementary root canals during endodontic procedure is the major reason in the failure of endodontic treatment.<sup>2</sup>

The root canal system generally exhibit variations in all teeth, but many dentists assume a standard

<sup>1</sup> Assistant Professor, Operative Dentistry, Institute of Dentistry, Liaquat University of Medical & Health Sciences, Jamshoro, Email: rajputfozia@yahoo.com, Cell: 0300-3060358

<sup>2</sup> Assistant Professor, Operative Dentistry, Institute of Dentistry, Liaquat University of Medical & Health Sciences, Jamshoro, Sindh. Email: dentistshaikh@yahoo.com Cell Number: 0333-2603050

<sup>3</sup> Assistant Professor & Vice Principal, Head of Department of Oral Surgery and Maxillofacial Surgery, Bibi Aseefa Dental College, Larkana, Sindh.

<sup>4</sup> Postgraduate M.Sc. Trainee, Operative Dentistry, Institute of Dentistry, Liaquat University of Medical & Health Sciences, Jamshoro

**Received for Publication:** February 1, 2014

**Revision Received:** February 15, 2014

**Revision Accepted:** February 17, 2014

number of root canals while performing root canal treatment, which may consequently lead to endodontic treatment failure. Root canal variation is very common in the permanent mandibular first molars leading us to assume the incidence of a fourth canal until confirmed otherwise by careful examination and exploration of the pulp chamber floor. The use of magnification, adequate lighting and modified access may aid the exact location of the root canals.<sup>3</sup>

A triangular shape outline of the access cavity for permanent mandibular first molars is usually designed. Current concepts of endodontic access cavity preparation suggest a wider access cavity so as to facilitate total exploration of the pulp chamber. The triangular shape of the access cavity preparation restricts the operator from being able to completely examine the pulp chamber floor. The modified access cavity preparation increases the likelihood of ruling a fourth canal.<sup>4</sup>

The purpose of this study was to evaluate the occurrence of the fourth canal in the permanent mandibular first molars and to find out the effect of modified shape of the access cavity from the triangular shape to the quadrangular shape on its frequency of fourth canal in the permanent mandibular first molars.

Till to date, no significant study has been performed as per author's knowledge, which records these variations in the Pakistani population. All the available data which is taught at the undergraduate as well as postgraduate level is obtained from research studies conducted in Europe and North America from Caucasian population. Furthermore studies conducted in other populations show a definite variation based on racial differences especially in the Asian population.<sup>5-9</sup>

The outcome of this study will therefore assist in performing endodontic treatment with improved understanding of the internal anatomy of the permanent mandibular first molars.

## METHODOLOGY

The study was carried out at the Department of Operative Dentistry, Institute of Dentistry, Liaquat University of Medical & Health Sciences, Jamshoro/Hyderabad, over a period of six months from September 2009 to February 2010. This included the time taken to collect and analyze the data.

Restorable 200 permanent mandibular first molars with fully formed roots were selected from 100 male and 100 female patients with no age restriction by

convenience sampling technique. Informed consent for the procedure was obtained from patients. Complete demographical data was recorded on a proforma; the proforma also recorded all the procedures and findings. A pre-operative radiograph was taken. Careful interpretation of the pulp chamber and the root canals was carried out and the number of root(s) / root canals identified.

After proper anesthesia and isolation with rubber dam, the pulp chamber was accessed using a diamond round bur in a high speed hand piece. Initially a standard triangular access cavity was prepared. The pulp chamber was then irrigated with a 2.5% sodium hypochlorite solution. The pulp chamber was then dried and carefully explored with a DG16 endodontic explorer and the number and location of the canal orifices was identified and noted on the proforma.

Then a modification of the access cavity was carried out to change the outline from a triangular to a quadrangular shape. The pulp chamber floor was again irrigated and dried and further exploration carried out to try and locate the fourth canal in the distal and distolingual area. Any subsequent finding was noted on the proforma.

Then two periapical radiographs at different angles were taken with 15 # K files in the root canals to confirm the number of root canals located. Endodontic treatment was then carried out to completion.

## DATA ANALYSIS

Data collected were entered on the SPSS version 10. The collected data were analyzed for the number of root canals in each root, proportion of patients with a fourth canal and increase in proportion of patients diagnosed with a fourth canal by modifying the shape of the access cavity preparation and by gender. The chi square test was applied.

## RESULTS

The results show that out of 200 permanent mandibular first molar teeth, 72(36%) had four canals, two in the mesial root and two in the distal root while 128(64%) had three canals, two in the mesial root and one in the distal root (Fig 1).

Out of 128 teeth, 3 canals were found in 110 cases with a triangular access cavity preparation while 18 cases were found having 3 canals with a quadrangular access cavity preparation.

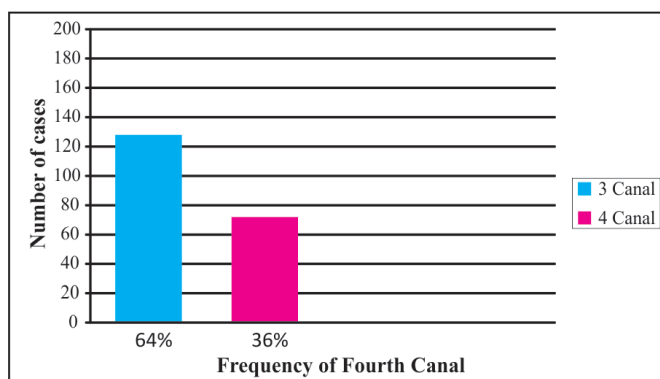


Fig 1: The frequency of 3 canals and 4 canals in permanent mandibular first molars n=200

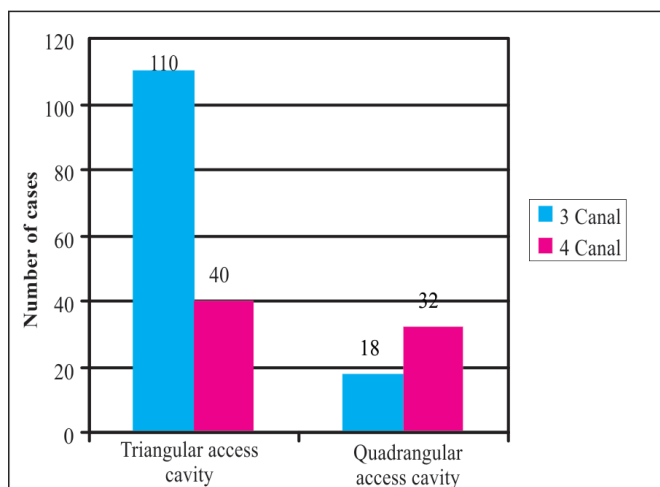


Fig 2: The frequency of 3 canals and 4 canals according to the shape of access cavity preparation n=200

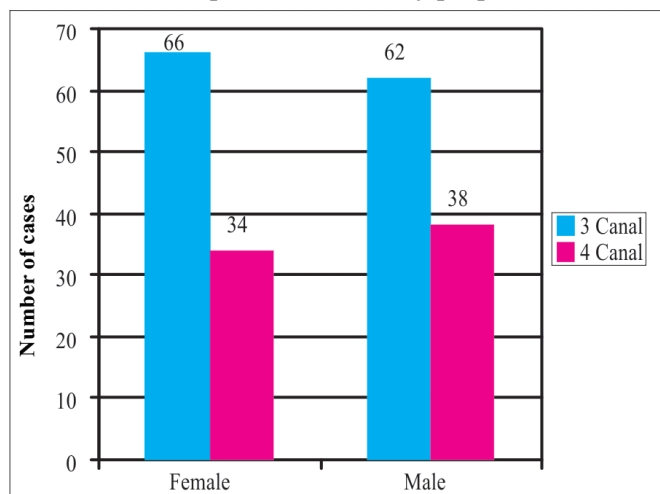


Fig 3: Frequency of 3 canals and 4 canals according to gender n=200

Out of 72 teeth, fourth canal were found in 40 cases with a triangular access cavity preparation but further exploration with a quadrangular access cavity preparation revealed 32 more cases with a fourth canal (Fig 2). Therefore the effect of modified access cavity preparation was significantly higher ( $P=0.0001$ ) in cases

with a fourth canal than in teeth with three canals ( $P=0.05$ ).

According to gender 38(38%) out of 100 male patients treated had a fourth canal in permanent mandibular first molars. Also 34(34%) out of 100 female patients treated had a fourth canal in permanent mandibular first molars (Fig 3). Statistically there was insignificant difference ( $P=0.7$ ) between the genders.

## DISCUSSION

For the success of endodontic treatment, a comprehensive knowledge of root and canal morphology, detailed interpretation of periapical radiographs, proper access cavity preparation and a detailed exploration of the interior of the tooth are essential prerequisites.<sup>10</sup> The failure in locating the canal is major reason of recurrence of endodontic infection after obturation.<sup>11</sup>

The mandibular first molar is most commonly treated tooth<sup>9</sup> and there is significant lower success rate of endodontic treatment of mandibular first molars than the other teeth<sup>12</sup> due to persistent infection caused by missing canal.<sup>13</sup>

The mandibular first molar has variations in root canal morphology.<sup>9</sup> According to reports of various in vitro as well as in vivo studies fourth canal is common finding in permanent mandibular first molars.<sup>6,9,14</sup> Many studies<sup>6,9,14</sup> have been conducted and reported that the incidence of four canals ranges from 4% to 57% in different populations.<sup>15</sup>

Different methodologies have been used to study the root canal morphology of the permanent mandibular first molar including clearing technique,<sup>6,7</sup> replication technique,<sup>9</sup> sectioning and macroscopic or Scanning Electron Microscopy (SEM) evaluation,<sup>16</sup> radiographs,<sup>17</sup> use of radiopaque dyes,<sup>17</sup> plastic resin injection,<sup>9</sup> micro-Computed Tomography (mCT),<sup>18</sup> Spiral Computed Tomography (SCT),<sup>19</sup> Cone Beam Computed Tomography (CBCT).<sup>20</sup> All above methods may have shortcomings.

The conventional radiograph is the only routine chair-side method to visualize the structure of the tooth during endodontic treatment but it does not provide complete picture of internal anatomy of tooth.

In the present study, two periapical radiographs were taken at different angles to confirm the number of root canals located.

The use of a dental operating microscope has proved to be an important clinical tool because it has helped tremendously in locating additional canals.<sup>21</sup>

Hartwell G and Bellizzi R in 1982 conducted an in vivo study in 846 endodontically treated permanent

mandibular and maxillary molars using periapical radiographs, reported that fourth canal was found in 35.1% of 297 mandibular first molars in total sample size.<sup>22</sup>

Fabra Campos H in 1985 examined 145 mandibular first molars clinically and radiographically, fourth canal was found in 47.6% (69 out of 145) of examined teeth.<sup>23</sup>

In 1999, Al-Nazhan S examined two hundred and fifty one root canal treated permanent mandibular first molars clinically and radiographically in Saudi Arabian subpopulation. Fourth canal was found in 57.76% of total examined teeth.<sup>24</sup>

Retrospective studies<sup>25,26</sup> revealed that fourth canal was present in 31.5% and 29.9% respectively in permanent mandibular first molars.

The findings of present study revealed that fourth canal was found in 36% (72 out of 200 teeth) of permanent mandibular first molars in the total treated patients.

The incidence of fourth canal in this study is equal to finding of study conducted by Chourasia HR,<sup>27</sup> but higher than studies conducted by Hartwell G,<sup>22</sup> Yew SC,<sup>26</sup> Zaatar EI,<sup>25</sup> Sperber GH,<sup>16</sup> Gulabivala K,<sup>28</sup> Reuben J,<sup>19</sup> de Pablo OV,<sup>29</sup> and lower than studies conducted by Fabra Campos H,<sup>23</sup> Al-Nazhan S,<sup>24</sup> Ahmed HA,<sup>30</sup> Pattanshetti N,<sup>31</sup> Chen G,<sup>15</sup> Wang Y,<sup>20</sup> Zhang R,<sup>32</sup> Kim SY.<sup>33</sup>

The high frequency with which a fourth canal was found leads us to believe that the fourth canal is a very frequently occurring variation in the permanent mandibular first molars, therefore every effort should be made to locate fourth canal until proven there are only three canals.

The most important step in successfully locating the fourth canal is to establish excellent access to the entire pulp chamber.<sup>34</sup> The shape of the pulp chamber reflects the number of roots and canals. Teeth with three root canals have a triangular pulp chamber, whilst teeth with four canals have a quadrangular pulp chamber.<sup>16</sup> The standard access cavity preparation which is triangular in shape does not allow for exploration of the pulp chamber floor for a fourth canal.<sup>34</sup>

Due to the high incidence of fourth canal in permanent mandibular first molars, the conventional triangular access cavity should be extended towards the distolingual direction in order to improve canal identification.<sup>27</sup>

This was proved again in this study where in 32 out of 72 cases the fourth root canal was found only when the outline of the access cavity was extended from a triangular shape to a quadrangular shape. The shape

of the distal canal orifice was also helpful in predicting the presence of a fourth canal since during the study an oblong or bean shaped orifice nearly always lead to two canals. Also the extreme buccal or lingual position of the orifice was an indication of a fourth canal.

For the presence of fourth canal there was insignificant difference between genders in studies conducted by Al-Nazhan S in 1999,<sup>24</sup> Pattanshetti N and others in 2008,<sup>31</sup> and Kim SY and others in 2013,<sup>33</sup> findings of these studies are similar to findings of this study. The findings of present study showed that 34% female patients and 38% male patients treated had a fourth canal.

Various factors are related to differences in findings of conducted studies such as racial divergence, sample size, study design (ex vivo versus in vivo), technique of canal identification (sectioning, clearing, radiographic examination), classification systems, ethnic background of tooth sources and patient's age.<sup>17</sup>

The radiographs were found to be an integral part of the diagnostic as well as the procedural phases of endodontic treatment. The multiple periapical radiographs taken at different angles are considered as accepted methods because they create a three dimensional image and help to diagnose extra canals.<sup>2,35</sup>

In this investigation it is believed there was a combination of factors responsible for finding the fourth canal including recognizing its existence, pre-treatment radiographs, quadrangular access cavity shape, good exploration, and thorough radiographic analysis using the image cone shift technique.

Variations in the morphology of the dental pulp are caused by genetic, developmental as well as environmental influences, and there is clear cut need for clinicians to be made aware of the frequency of racially determined forms.<sup>5</sup> Therefore, a better understanding about root canal morphology is essential for improving the outcome of endodontic treatment of mandibular first molars.<sup>36</sup>

## CONCLUSIONS

Present study demonstrated that, there is a greater frequency of a fourth canal in the permanent mandibular first molar than previously thought. Based on this information more attention should be given to searching for locating and treating this canal. A mesial shift provides a better radiographic view of the roots helping in diagnosing canal structure. The shape of the access cavity should be quadrangular and not triangular, so that chance of missing a canal is minimized.

In light of the above findings, it is recommended that further research should be carried out to note all the variations in root canal morphology of permanent mandibular first molars in the local population.

REFERENCES

- 1 Burns RC, Herbranson EJ. Tooth morphology and cavity preparation. In: Cohen S, Burns RC (eds). *Pathways of the PULP*. 7th ed. St. Louis: Mosby, 1998; 210-28.
- 2 Slowey RR. Radiographic aids in the detection of extra root canals. *Oral Surg Oral Med Oral Pathol*. 1974 May; 37(5): 762-72.
- 3 Favieri A, Barros FG, Campos LC. Root canal therapy of a maxillary first molar with five root canals: case report. *Braz Dent J*. 2006; 17(1): 75-8.
- 4 Walton RE, Vertucci FJ. Internal Anatomy. In: Walton RE, Torabinejad M (eds). *Endodontics: Principles and practice*. 3rd ed. Philadelphia: WB Saunders, 2002: 168-9.
- 5 Goel NK, Gill KS, Taneja JR. Study of root canals configuration in mandibular first permanent molar. *J Indian Soc Pedod Prev Dent*. 1991 Mar; 8(1): 12-4.
- 6 Vertucci FJ. Root canal anatomy of the human permanent teeth. *Oral Surg Oral Med Oral Pathol*. 1984 Nov; 58(5): 589-99.
- 7 Gulabivala K, Opananon A, Ng YL, Alavi A. Root and canal morphology of Thai mandibular molars. *Int Endod J*. 2002 Jan; 35(1): 56-62.
- 8 Wasti F, Shearer AC, Wilson NHF. Root canal systems of the mandibular and maxillary first permanent molar teeth of South Asian Pakistanis. *Int Endod J*. 2001; 34: 263-6.
- 9 Skidmore AE, Bjorndal AM. Root canal morphology of the human mandibular first molar. *Oral Surg Oral Med Oral Pathol*. 1971 Nov; 32(5): 778-84.
- 10 Vertucci FJ. Root canal morphology and its relationship to endodontic procedures. *Endodontic Topics*. 2005; 10: 3-29.
- 11 Cohen S, Hargreaves KM. *Pathways of the pulp*. 9th ed. St. Louis: Mosby. 2006: 149.
- 12 Swartz DB, Skidmore AE, Griffin JA. Twenty years of endodontic success and failure. *J Endod*. 1983 May; 9(5): 198-202.
- 13 Cohen S, Hargreaves KM. *Pathways of the pulp*. 9th ed. St. Louis: Mosby. 2006: 220.
- 14 Green D. Morphology of the pulp cavity of the permanent teeth. *Oral Surg Oral Med Oral Pathol*. 1955 Jul; 8(7): 743-59.
- 15 Chen G, Yao H, Tong C. Investigation of the root canal configuration of mandibular first molars in a Taiwan Chinese population. *Int Endod J*. 2009 Nov; 42(11): 1044-9.
- 16 Sperber GH, Moreau JL. Study of the number of roots and canals in Senegalese first permanent mandibular molars. *Int Endod J*. 1998 Mar; 31(2): 117-22.
- 17 Pineda F, Kuttler Y. Mesiodistal and buccolingual roentgenographic investigation of 7,275 root canals. *Oral Surg Oral Med Oral Pathol*. 1972 Jan; 33(1): 101-10.
- 18 Gu L, Wei X, Ling J, Huang X. A microcomputed tomographic study of canal isthmuses in the mesial root of mandibular first molars in a Chinese population. *J Endod*. 2009 Mar; 35(3): 353-6.
- 19 Reuben J, Velmurugan N, Kandaswamy D. The evaluation of root canal morphology of the mandibular first molar in an Indian population using spiral computed tomography scan: an in vitro study. *J Endod*. 2008 Feb; 34(2): 212-5.
- 20 Wang Y, Zheng QH, Zhou XD, Tang L, Wang Q, Zheng GN, et al. Evaluation of the root and canal morphology of mandibular first permanent molars in a western Chinese population by cone-beam computed tomography. *J Endod*. 2010 Nov; 36(11): 1786-9.
- 21 Yoshioka T, Kobayashi C, Suda H. Detection rate of root canal orifices with a microscope. *J Endod*. 2002 Jun; 28(6): 452-3.
- 22 Hartwell G, Bellizzi R. Clinical investigation of in vivo endodontically treated mandibular and maxillary molars. *J Endod*. 1982 Dec; 8(12): 555-7.
- 23 Fabra-Campos H. Unusual root anatomy of mandibular first molars. *J Endod*. 1985 Dec; 11(12): 568-72.
- 24 al-Nazhan S. Incidence of four canals in root-canal-treated mandibular first molars in a Saudi Arabian sub-population. *Int Endod J*. 1999 Jan; 32(1): 49-52.
- 25 Zaatari EI, al-Kandari AM, Alhomaidah S, al-Yasin IM. Frequency of endodontic treatment in Kuwait: radiographic evaluation of 846 endodontically treated teeth. *J Endod*. 1997 Jul; 23(7): 453-6.
- 26 Yew SC, Chan K. A retrospective study of endodontically treated mandibular first molars in a Chinese population. *J Endod*. 1993 Sep; 19(9): 471-3.
- 27 Chourasia HR, Meshram GK, Warhadpande M, Dakshindas D. Root canal morphology of mandibular first permanent molars in an Indian population. *Int J Dent*. 2012; 2012: 745152. doi: 10.1155/2012/745152. Epub 2012 Jan 11.
- 28 Gulabivala K, Opananon A, Ng YL, Alavi A. Root and canal morphology of Thai mandibular molars. *Int Endod J*. 2002 Jan; 35(1): 56-62.
- 29 de Pablo OV, Estevez R, Péix Sánchez M, Heilborn C, Cohenca N. Root anatomy and canal configuration of the permanent mandibular first molar: a systematic review. *J Endod*. 2010 Dec; 36(12): 1919-31.
- 30 Ahmed HA, Abu-bakr NH, Yahia NA, Ibrahim YE. Root and canal morphology of permanent mandibular molars in a Sudanese population. *Int Endod J*. 2007 Oct; 40(10): 766-71.
- 31 Pattanshetti N, Gaidhane M, Al Kandari AM. Root and canal morphology of the mesiobuccal and distal roots of permanent first molars in a Kuwait population—a clinical study. *Int Endod J*. 2008 Sep; 41(9): 755-62.
- 32 Zhang R, Wang H, Tian YY, Yu X, Hu T, Dummer PM. Use of cone-beam computed tomography to evaluate root and canal morphology of mandibular molars in Chinese individuals. *Int Endod J*. 2011 Nov; 44(11): 990-99.
- 33 Kim SY, Kim BS, Woo J, Kim Y. Morphology of mandibular first molars analyzed by cone-beam computed tomography in a Korean population: variations in the number of roots and canals. *J Endod*. 2013 Dec; 39(12): 1516-21.
- 34 Ingle JI, Himel VT, Hawrish CE, Glickman GN, Serene T, Rosenberg PA, et al. Endodontic cavity preparation. In: Ingle JI, Bakland LK (eds). *Endodontics*. 5th ed. Ontario: BC Decker Inc, 2002; 405-530.
- 35 Walton RE. Endodontic radiographic techniques. *Dent Radiogr & Photogr*. 1973; 46(3): 51-9.
- 36 Chen YC, Lee YY, Pai SF, Yang SF. The morphologic characteristics of the distolingual roots of mandibular first molars in a Taiwanese population. *J Endod*. 2009 May; 35(5): 643-45.