

EVALUATION OF PATTERNS OF MANDIBULAR THIRD MOLAR IMPACTIONS AND ASSOCIATED PATHOLOGIES

¹MUHAMMAD ASIF SHAHZAD

²MOMIN AYUB MARATH

³M RAFIQUE CHATHA

⁴AQIB SOHAIL

ABSTRACT

Mandibular third molar is the most common tooth to become impacted. Mandibular third molars may acquire a range of patterns and positions and may lead to a diverse group of pathologies. The objective of this study was to enlist the different patterns of mandibular third molar impactions and their associated pathologies. This descriptive study was carried out at Oral and Maxillofacial Surgery Unit of Lahore Medical & Dental College, Lahore from February 2014 to September 2015. A total of 271 patients with 382 impacted mandibular third molars were included in the current study. Their ages were between 20 to 53 years (Mean±SD, 27.81±7.37). 114 (42.07%) were male and 157 (57.93%) females with male to female ratio of 1:1.38. Patients were evaluated with thorough history, clinical and radiographic examination. Periapical and panoramic radiographs were used to assess the pattern of mandibular third molar impactions and their associated pathologies. Mesioangular angulation (45.55%) with class II ramus relation (60.73%) and Position A (54.71%) depth was the most frequent pattern of impaction. A total of 324 pathologies were seen in 271 patients who presented for removal of impacted mandibular third molars. The most common pathology associated with the impacted mandibular third molar was dental caries of third molar (38.89%), followed by pericoronitis (29.01%, periodontal disease (14.19%) and a low frequency of cysts and tumors (3.39%). Prophylactic removal of impacted mandibular third molar with unfavorable patterns and positions may be beneficial for the patients to prevent the patients from associated pathologies.

Key Words: Impacted mandibular third molar, dental caries, pericoronitis, odontogenic cysts, odontogenic tumors.

INTRODUCTION

Impacted teeth are those which fail to erupt or develop into the proper functional location. Impacted teeth may be non-functional, abnormal, or associated with the pathology.¹ Any tooth may become impacted but the most common are mandibular third molars. Mandibular third molars may become impacted because

of adjacent teeth, dense overlying bone or soft tissue, lack of space in the jaw, aberrant path of eruption, abnormal positioning of tooth bud or pathological lesions.² Mandibular third molars erupt at 17 to 21 years age and frequency of impaction is more in mandible than maxilla, with significantly higher frequency in females than males.^{3,4,5}

Mandibular third molars may acquire a range of patterns and positions and can lead to diverse pathologies. The position of an impacted third molars are categorized radiographically according to the anterior posterior space between the second molar and the mandibular ramus, its superior-inferior position, its medial lateral position in the body of the mandible and the position of its long axis, this classification is universally accepted, easy to coordinate between oral surgeons and even in record maintaining, treatment planning.⁶

Impacted mandibular third molars may lead to a diverse group of pathologies including pericoronitis, dental caries of third molar or adjacent second molar.

¹ Muhammad Asif Shahzad, BDS, FCPS, Assistant Professor, Department of Oral & Maxillofacial Surgery, Lahore Medical & Dental College, Lahore

² Momin Ayub Marath, BDS, M.Sc, Assistant Professor, Department of Oral Pathology, Lahore Medical & Dental College, Lahore

³ M Rafique Chatha, BDS, MDS (Hons), FCPS, Professor, Department of Oral & Maxillofacial Surgery/Principal Dental Section, Lahore Medical & Dental College, Lahore

⁴ Aqib Sohail, BDS, FCPS, MOMSRCPS (Glasgow), Professor, Department of Oral & Maxillofacial Surgery, Lahore Medical & Dental College, Lahore **For Correspondence:** Dr Muhammad Asif Shahzad, House No. 141-C, Punjab Co-operative Housing Society, DHA, Lahore. Email: drasif_395@hotmail.com
Cell: 0333-4336976

Received for Publication: May 3, 2016

Revised: May 26, 2016

Approved: May 28, 2016

There could also be root resorption of second molar, periodontal problems, odontogenic cysts and tumors etc.^{7,8} The aim of this study was to enlist the different patterns of mandibular third molar impactions and their associated pathologies. This will guide the surgeons not only to decide about the prophylactic removal of impacted mandibular third molars but also help in better treatment planning for the associated pathologies.

METHODOLOGY

This descriptive study was conducted from February 2014 to September 2015 in the Department of Oral and Maxillofacial Surgery, Lahore Medical and Dental College, Lahore, Punjab, Pakistan. All patients presenting in outdoor patients department of Oral & Maxillofacial Surgery were examined by the team of this study. Inclusion criteria consisted of complete root formation of impacted mandibular third molars, patients with symptomatic impacted mandibular third molars or their associated pathologies. Patients younger than 20 years, maxillofacial trauma, systemic or craniofacial anomaly, syndrome and absence of mandibular second molar were excluded from the study. A total of 271 patients having impacted mandibular third molars or their associated pathologies were included in the study. A written informed consent was obtained from the patient. Patients' demographic details (age and gender), side of impaction (right or left), type of impaction (partially or fully impacted) and associated pathologies/radiolucency were recorded in a specially designed proforma.

The assessment of angulations, patterns and positions of impacted mandibular third molars and their associated pathologies was done by detailed relevant history, clinical examination and radiographs i.e. periapical and panoramic views (OPG). Angulation of impacted mandibular third molars was assessed by Winter's classification and teeth were labeled as mesioangular, distoangular, vertical or horizontal and other impactions (buccal, lingual or transverse). Patterns and positions of impacted third molar were documented according to Pell and Gregory classification. If space between anterior border of ramus and distal surface of second molar was sufficient, it was labeled Class I. If space was less than mesiodistal diameter of impacted tooth, it was termed Class II. A tooth completely into ramus was assigned Class III. A third molar with its highest part at level of occlusal plane of second molar was assigned position A. In position B, impacted tooth was between occlusal plane and cervical margin of second molar while a tooth below cervical margin was labeled position C.

Impacted mandibular third molar associated pathologies (pericoronitis, dental caries of second or third molar, periodontal defect, root resorption of second

molar) were also recorded. Definitive diagnosis of cysts and tumors was made from histopathological report of specimen taken while managing the impacted third molars (Fig 1-4).

Data was analyzed in SPSS version 17 by using Chi Square test. The qualitative variables in the demographic data like gender, patterns of impaction and associated pathologies were presented as proportions and percentages and quantitative variables like age were presented as means and standard deviation. The association between angulation, ramus relation and depth of impaction with age and gender were tested by using Chi Square test. The admitted level of significance was $p < 0.05$.

RESULTS

A total of 271 patients having 382 impacted mandibular third molars were included in the current study. The ages of patients range from 20 to 53 (Mean \pm SD, 27.81 ± 7.37). 114 (42.07%) were male and 157 (57.93%) females with male to female ratio of 1:1.38 (Table 1). Three hundred and eighty two impacted mandibular third molars were evaluated. Most of the impactions, 161 (42.15%) were in the age group 20-25, followed by 82 (21.47%) in 26-30 and 66 (17.28%) in 31-35 age groups.

According to Winter's classification, mesioangular impactions were the most common 174 (45.55%), followed by vertical 121 (31.68%), 52 (13.61%) distoangular, 33 (8.64%) horizontal and 02 (0.52%) others (Table 2). Assessing the level of impaction using the Pell and Gregory classification, showed that 209 (54.71%) were in position A, 127 (33.25%) in position B and 46 (12.04%) in position C. 232 (60.73%) were in position II, 87 (22.78%) in position I and 63 (16.49%) in position III.

A total of 324 pathologies were seen in 271 patients who presented for removal of impacted mandibular third molars. The most frequent reason for extraction of third molar was dental caries in third molar itself

TABLE 1: AGE AND GENDER DISTRIBUTION

Age groups (years)	Male	Female	Total	Percentage
20-25	45	72	117	43.17%
26-30	26	31	57	21.03%
31-35	18	28	46	16.97%
36-40	14	17	31	11.44%
41-45	06	06	12	04.43%
46-50	02	07	03	01.11%
>50	03	02	05	01.85%
Total	114	157	271	100.00%

TABLE 2: AGE DISTRIBUTION OF TYPE OF IMPACTION (N=271, NO. OF IMPACTIONS=382)

Type of Impaction	Age groups (years)							Total	Per-centage
	20-25	26-30	31-35	36-40	41-45	46-50	>50		
Mesioangular	73	39	28	19	06	02	07	174	45.55%
Vertical	52	27	23	18	01	—	—	121	31.68%
Distoangular	16	07	13	08	06	01	01	52	13.61%
Horizontal	19	09	02	01	02	—	—	33	08.64%
Others	01	—	—	01	—	—	—	02	00.52%
Total	161	82	66	47	15	03	02	382	100.00%

TABLE 3: DISTRIBUTION OF PATHOLOGY; ANGULATION WISE (N=271, PATHOLOGY=324)

Pathology	Mesioangular	Vertical	Horizontal	Distoangular	Other	Total
Caries (3rd Molar)	68	38	11	08	01	126
Pericoronitis	42	26	03	23	—	94
Periodontal problem	21	19	—	06	—	46
Caries (2nd Molar)	14	02	06	03	—	25
Root Resorption (2nd Molar)	15	—	07	—	—	22
Cyst	04	02	—	—	01	07
Tumor	03	—	—	01	—	04
Total	157	87	27	41	02	324

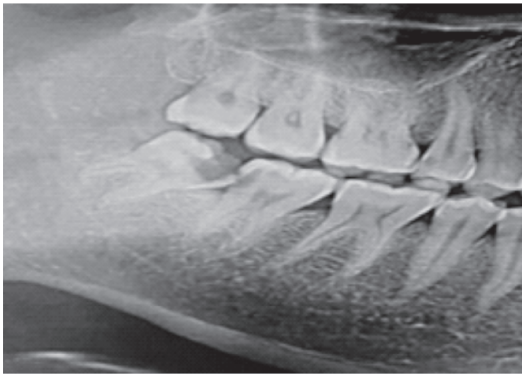


Fig 1: Dental caries of impacted mandibular third molar itself

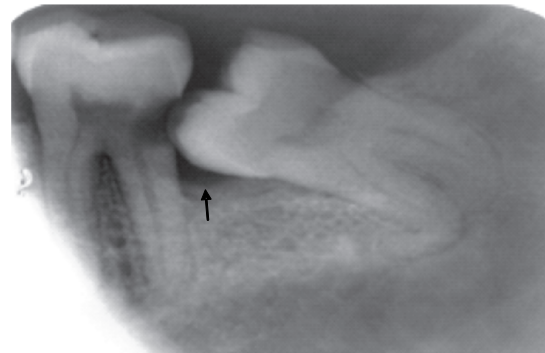


Fig 3: Dental caries and periodontal disease of mandibular second molar

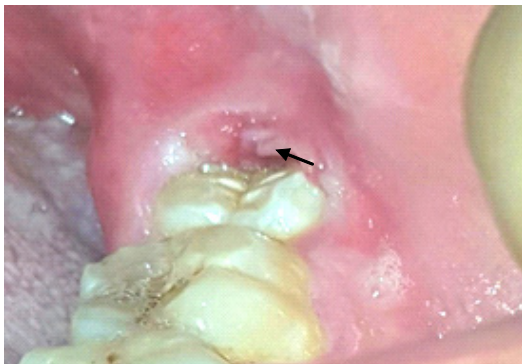


Fig 2: Pericoronitis around left impacted mandibular third molar

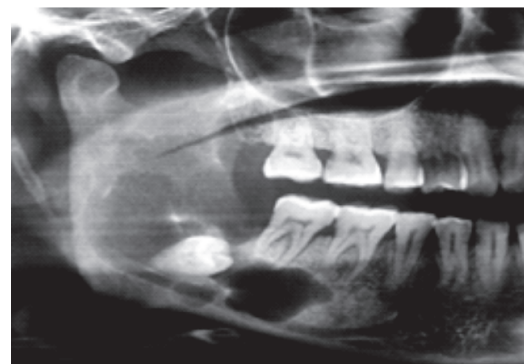


Fig 4: A radiolucent pathological lesion associated with impacted mandibular third molar

(38.89%) followed by pericoronitis (29.01%), periodontal pathology (14.19%), caries of adjacent second molar (7.72%), root resorption of adjacent second molar caused by impacted mandibular third molar (6.79%) and cysts/tumors (3.39%) (Table 3). More than half of the pathologies were seen in impacted third molars with class II ramus relationship and position A depth. There was no statistically significant relationship of age and gender with angulation, ramus relation and depth of impacted mandibular third molars ($p>0.05$).

DISCUSSION

The third molar teeth are the last to erupt with a relatively high chance of becoming impacted. The retained, unerupted mandibular third molars are often associated with varied pathologies such as caries, pericoronitis, periodontal disease, cystic lesions, benign and malignant tumors, pathologic root resorption along with detrimental effects on adjacent teeth.⁹

The removal of impacted molars is a frequently performed oral surgical procedure worldwide^{8,10} and also at minor oral surgery clinic of Lahore Medical and Dental College, Lahore, Pakistan. The present study was conducted on patients over 20 years, because by this age, one can differentiate more reliably if third molar has insufficient space or is improperly positioned or its root formation has completed.⁵

Patients in their third decade of life were seen with highest percentage of impacted mandibular third molar impaction which correlates with the studies done in past in Pakistan and other countries.¹¹ This study also indicates that females were commonly affected with molar impaction as compared to males and this finding is in accordance with other studies regarding gender distribution.^{11,12} In our study, there was very less number of patients in the last two age groups as compared to other groups and this could be due to early removal and neglected oral hygiene maintenance.¹³

The literature shows the variation in the frequency of occurrence of different angular positions and ramus relationship of the impacted lower third molar. The results of our study show that mesioangular impactions were the most common, followed by vertical, distoangular and horizontal angulations. About 60% patients had a ramus relationship of class II, followed by class I and class III. About 54% patients had impacted third molar placed at position A depth, followed by position B and C. These results are comparable with Stanley et al¹⁴ and Knutsson et al¹⁵ but unlikely with Sasano T¹⁶, Venta et al¹⁷ which showed the common impaction according to Winter's classification was vertical.

In the current study, a total of 324 pathologies were seen in 271 patients who presented for removal of impacted mandibular third molars. The most

frequent reason for removal of third molar was the dental caries of third molar itself (38.89%), followed by pericoronitis (29.01%) and periodontal problem (14.20%). These observations are different from other studies done in Pakistan and other countries^{6,18} which show pericoronitis was the most common reason for removal of impacted mandibular third molar but are in accordance with done by Nazir A et al.¹⁹

Knutsson et al¹⁵, Sasano T¹⁶, Venta et al¹⁷, and Punwutikorn et al²⁰ showed that there was high risk of developing pericoronitis in distoangular and vertical position impaction, This should be explained in terms that food impaction was common in such types of impactions but the results of our study indicate that pericoronitis was the most common finding in mesioangular impactions. Also the higher proportion of patients having dental caries and periodontal disease in the present study than others can be attributed to lack of oral health care taken by the population under study.

Most of the studies in the literature showed very low prevalence of cyst and tumor development associated with impacted third molar. This information is used to support the rationale for no treatment of asymptomatic impacted teeth.^{10,21,22} Only a small percentage of current study comprised of radiographic cystic changes (1.83%) or tumor (1.04%). This could be due to the fact that teeth with pathological process e.g. odontogenic cysts or tumors, take longer to make a third molar symptomatic and patients present at later age for removal of lesion and third molar. However, the highest numbers of cystic lesions were seen in patients of third decade of life. This could be a justification for prophylactic removal of impacted mandibular third molars in certain patients.^{7,22} It is worth mentioning at this stage that a number of cases are misdiagnosed histopathologically. This again signifies the importance of liaison between the surgeon and the pathologist. It will help in making a correct initial diagnosis and save the patients from waste of time, money and the morbidity caused by additional surgical procedures. It is also recommended that patients should be educated with regards to regular dental checkups and improved oral health for reducing the prevalence of impacted mandibular third molar related caries and other associated pathologies in the population. Also that oral histopathological service should be established as there is a lack of such facilities.

CONCLUSION/RECOMMENDATIONS

Impacted mandibular third molars were most commonly seen in age groups (20-25 years) and (26-30 years). Mesioangular and vertical were the most common impactions seen in this study with common pathologies of dental caries and pericoronitis. Pro-

phylactic extraction of impacted mandibular third molar may be beneficial for the patients. Moreover, early diagnosis of associated pathologies and proper management of impacted mandibular third molar is necessary to prevent further consequences. However, there is need for a population based study in Pakistan for effective planning as it is a small representative sample.

REFERENCES

- Nazir R, Amin E, Jan HU. Prevalence of impacted ectopic teeth in patients seen in a tertiary care center. *Pakistan Oral & Dent J* 2009; 29: 297-300.
- Ishihara Y, Kamioka H, Yamamoto TT, Yamashiro T. Patients with nonsyndromic bilateral and multiple impacted teeth and dentigerous cysts. *Am J Orthod Dentofacial Orthop* 2012; 141: 228-41.
- Sheikh MA, Riaz M, Shafiq S. Incidence of distal caries in mandibular second molars due to impacted third molars – A clinical & radiographic study. *Pakistan Oral & Dent J* 2012; 32: 364-70.
- Hashemipour MA, Arashlow MT, Hnzaei FF: Incidence of impacted mandibular and maxillary third molars: A radiographic study in a Southern Iran population. *Med Oral Patol Oral Cir Bucal* 2013; 18: 40-45.
- Hassan AH. Pattern of third molar impactions in a Saudi population. *Clin Cosmet Investig Dent* 2010; 2: 109-13.
- Ma'aita JK. Impacted third molars and associated pathology in Jordanian patients. *Saudi Dent J* 2000; 12: 16-19.
- Syed KB, Kota Z, Ibrahim M, Bagi MA, Assiri MA. Prevalence of impacted molar teeth among Saudi population in Asir region, Saudi Arabia – A retrospective study of 3 years. *J Int Oral Health* 2013; 5: 43-47.
- Razavi SM, Hashemina D, Mehdizade M, Movahedian B, Keshani F. The relation of pericoronar third molar follicle dimension and bcl-2/ki-67 expression: An immunohistochemical study. *Dent Res J* 2012; 9: 26-31.
- Anibor E, Mabel O et al. Prophylactic Extraction of Third Molars in Delta State, Nigeria. *Archives of Applied Sciences Research*, 2011; 3: 364-68.
- Krishnan B, El Sheikh MH, El-Gehani R, Orafi H. Indications for removal of impacted mandibular third molars: a single institutional experience in Libya. *J Maxillofac Oral Surg* 2009; 8: 246-48.
- Ishfaq M, Wahid A, Rahim AU, Munim A. Patterns and presentations of impacted mandibular third molars subjected to removal at Khyber College of Dentistry, Peshawar. *Pakistan Oral & Dent J* 2006; 26: 221-26.
- Jaffar R, Tin M. Impacted mandibular third molars among patients attending Hospital University Sains Malaysia. *Arch Orol Sci* 2009; 4: 7-12.
- Khan A, Khitab U, Khan MT. Impacted third Molars: Pattern of presentation and complications. *Pakistan Oral & Dent J* 2010; 2: 307-12.
- Stanley HR, Alattar M, Collett WK et al. Pathological sequelae of "neglected" impacted third molars. *J Oral Pathol* 1988; 17: 113-17.
- Knutsson K, Brehmer B, Lysell L, Rohin M. Pathoses associated with mandibular third molars subject to removal. *Oral Surg Oral med Oral Pathol Oral Radiol* 1996; 82: 10-17.
- Sasano T, Kuribara N, Iikubo M, Yoshida A et al. Influence of angular position and degree of impaction of third molars on development of symptoms: Long term follow-up under good oral hygiene conditions. *Tohoku J Exp Med* 2003; 200: 75-83.
- Venta I, Turtola L, Murtomaa H, Ylipaavalniemi P. Third molars as an acute problem in Finnish University Students. *Oral Surg Oral Med Oral Pathol* 1993; 76: 135-40.
- Ishfaq M, Wahid A, Rahim A, Munim A. Patterns and presentations of impacted mandibular third molars subjected to removal at Khyber College of Dentistry, Peshawar. *Pakistan Oral & Dent J* 2006; 26: 221-26.
- Nazir A, Akhtar MU, Ali S. Assessment of different patterns of impacted mandibular third molars and their associated pathologies. *J Adv Med Dent Scie* 2014; 2(2): 14-22.
- Punwutikom J, Waikakul A, Ochareon P. Symptoms of unerupted third molars. *Oral Surg Oral med Oral Pathol Oral Radiol & Endo* 1999; 87: 305-10.
- Jung YH, Cho BH. Prevalence of missing and impacted third molars in adults aged 25 years and above. *Imaging Sci Dent* 2013; 43: 219-25.
- Stathopoulos P, Mezitis M, Kappatos C, Titsinides S, Stylogianni E. Cysts and tumors associated with impacted third molars: is prophylactic removal justified? *J Oral Maxillofac Surg* 2011; 69: 405-08.

CONTRIBUTIONS BY AUTHORS

- Muhammad Asif Shahzad:** Made substantial contribution in title selection, design planning, abstract & introduction, data collection, analysis, discussion and references writing.
- Momin Ayub Marath:** Participation in design planning, writing introduction, data collection, conclusion and references writing.
- M Rafique Chatha:** Supervision, final review.
- Aqib Sohail:** References writing, review