

## AMELOBLASTOMA IN YOUNG PERSONS: A RETROSPECTIVE STUDY OF THE CLINICOPATHOLOGIC FEATURES AND TREATMENT OF 19 CASES FROM A SEMI-URBAN NIGERIAN TEACHING HOSPITAL

\*H.O OLASOJI, B.ch.D, FMCDs (Nig)

\*\*U.H PINDIGA, FWACS

\*\*\*A.A TAHIR, MBBS, FWACS

### ABSTRACT

19 cases of ameloblastoma of the jaws in children and young adolescents were reviewed. During the period of evaluation, 113 patients with ameloblastoma of the craniofacial region were managed of which 16.8% were inpatients aged < 18 years. The mean (SD) age of patients was 14.7 ( $\pm 2.5$ ) years (range, 10-18 years). Male to female ratio 2:1; and mandible to maxilla ratio 18:1. Duration of the tumours at presentation ranged from 8 months to 5 years, (mean: SD = 3.3:1.5 years), 73.7% were of the multilocular type on radiographs and the most frequent histologic pattern was the plexiform type (n=12, 63.2%). Due to the large size at presentation, radical mandibulectomy was the method of treatment in 12 cases (63.2%). Recurrence was noticed in 4 patients (21%) within 5 years after primary surgery.

Ameloblastoma is relatively rare in Nigerian children, the clinical features, radiologic and histologic patterns however, were found to be similar to that of adults.

Key words: Ameloblastoma, young patients, clinicopathologic features, radiologic types, treatment.

---

### INTRODUCTION

Ameloblastoma is an epithelial tumour that develops before the formation of calcified dental tissues.<sup>1,2</sup> It is clinically described as a benign but locally aggressive and infiltrative odontogenic neoplasm with a rare capacity to metastasise.<sup>1,3</sup> Although ameloblastoma is reported to constitute only 1-3% of all jaw tumours and cysts, it is the most common odontogenic neoplasm; its frequency known to equal or exceed that of the other odontogenic tumours combined.<sup>3,4</sup>

Ameloblastoma is rare in childhood. A review of the literature shows that this tumour is found mainly in the middle age group.<sup>5,6</sup> Recent reports from developing countries suggest that ameloblastoma tends to occur in relatively young patients in these countries.<sup>7,8</sup> There are however, few studies especially from Africa, which specifically reported the pattern of presentation and management of ameloblastoma in children. The study is aimed at documenting the clinical characteristics, radiologic pattern, histologic types and treatment of 19 cases of ameloblastoma seen in patients aged 18 years

---

\* Consultant, Oral/Maxillofacial Surgeon, Department of Dental Surgery, University of Maiduguri Teaching Hospital, Maiduguri — Nigeria

\*\* Consultant Histopathologist, Department of Pathology, University of Maiduguri Teaching Hospital, Maiduguri — Nigeria

\*\*\* Consultant Radiologist, Department of Radiology, University of Maiduguri Teaching Hospital, Maiduguri — Nigeria

Correspondence Address: Dr H.O Olasoji, Consultant, Oral & Maxillofacial Surgeon, Maxillofacial Unit, Department of Dental Surgery, University of Maiduguri Teaching Hospital, P.M.B 1414, Maiduguri Nigeria. [E-mail: soji273@yahoo.com](mailto:soji273@yahoo.com)

and younger over a 7-year period in a semi-urban Nigeria teaching hospital.

## PATIENTS AND METHODS

We retrospectively reviewed the clinical records of the 113 patients managed for ameloblastoma of the jaws at the maxillofacial unit, University of Maiduguri teaching hospital, Nigeria between January 1993 and December 1999. This hospital is the only referral centre where oral and maxillofacial services were available in northeastern Nigeria with a population of approximately 15 million people. The data of patients less than 18 years of age was subjected to analysis of age and sex, bone and site affected by the tumour, duration of lesion, radiologic pattern, treatment methods and complications. Hematoxylin and eosin-stained sections were re-evaluated for each case and classified according to World Health Organisation (WHO) 1992 classification.<sup>9</sup> Data was analyzed using SPSS for window (version 11.0; SPSS Inc., Chicago, IL).

## RESULTS

A total of 113 patients with ameloblastoma of the jaw reported for treatment at our centre during the period under review. Nineteen patients (16.8%) were 18 years of age or younger and this group form the bases of this study. Their ages ranged from 10 to 18 years; mean (SD) 14.7 (2.5) years. There were 12 male patients (68.4%) and 7 females (31.6%); a male-to-female ratio of 2:1.

The duration of the tumour at the time of presentation in the hospital ranged from 8 months to 5 years with a mean (SD) of 3.3 (1.5) years. None of the lesion was discovered accidentally in a routine dental examination or radiographs. Facial deformity due to swelling of the jaw was the main complaint in 18 of the 19 patients, while one patient complained principally of pain, which was due to secondary infection. Displacement and loosening of teeth were common.

Table 1 showed the site of tumour involvement and indicates the preponderance of the lower jaw lesions constituting eighteen of the nineteen cases (94.7%) in this series. Of the 18 mandibular lesions, 9 (50%) were in the anterior part, 3 (16.7%) in the body, 2 (11.1%) were located in the ascending ramus while 4 (22.2%) involved the body-ramus region. The only tumour in

the maxilla was in the posterior region. In most of the cases it was not possible to delineate the exact site of the origin of the tumour, because of the extensive involvement of the jaws on presentation.

Radiological investigation revealed that majority of the tumour (n = 14, 73.7%) showed multilocular radiolucent or soap bubble appearance. 5 (26.3%) had unilocular appearance and, of these, three contained unerupted teeth mimicking the appearance of a dentigerous cyst. Sixteen patients had incisional biopsy before treatment, while in the 3 cases with a dentigerous cyst appearance; the diagnosis was made after treatment. Histologically, two types were observed, the plexiform type (n = 12, 63.2%) and follicular type (n = 7, 36.8%). 2 of the 3 cases with dentigerous cyst appearance were found to be unicystic (mural type).

In this series, the treatment of ameloblastoma was surgical. Radical mandibulectomy (hemimandibulectomy, segmental, and subtotal resections), including 1 cm of apparent normal bone was done in 12 cases (63.2%). This procedure was reserved for lesions in which the cortical bone of the inferior border of the horizontal ramus or the posterior border of the vertical ramus was involved. In 4 patients, marginal jaw resections were carried out with preservation of uninvolved cortical bone. Immediate reconstruction of the jaw was done with stainless steel/vitalium wires, Kirschner wires and arch bars in patients with jaw continuity defect. Only three patients returned for further reconstructive surgery with rib bone graft. In the 3 patients in which the radiological features of the lesion resemble dentigerous cysts, enucleation was the treatment of choice, however the diagnosis of ameloblastoma was made after histological review.

There was no mortality. However, in 2 patients, the metallic implants failed within eighteen months of insertion as a result of ulceration of the prosthesis through the skin following an infective process, which was eventually controlled with wound debridement and antibiotics. Tumour recurrence was observed in four patients (21%) within 5 years after primary surgery; these include 1 case with segmental resection, 2 cases with marginal jaw resection and 1 case with conservative treatment (enucleation).

TABLE 1: AGE, SEX, LOCATION, RADIOGRAPHIC APPEARANCE AND HISTOLOGIC TYPES IN 19 CASES OF AMELOBLASTOMA IN YOUNG NIGERIANS

<b>No</b>	<b>Age</b>	<b>Sex</b>	<b>Location</b>	<b>Radiographic appearance</b>	<b>Histologic types</b>
1	18	F	Left maxilla pre molar/ molar area	Multilocular	Plexiform
2	17	M	Left central incisor to left angle	Multilocular	Plexiform
3	17	M	Right canine to right second molar	Multilocular	Follicular
4.	18	M	Left central incisor to right first premolar	Multilocular	Plexiform
5.	10	F	Right canine to left first molar	Unilocular with embedded tooth	Plexiform
6.	15	M	Right first premolar to right TMJ	Multilocular	Plexiform
7	11	M	Right first premolar to left second premolar	Multilocular	Plexiform
8	16	M	Right second premolar to right angle	Unilocular with embedded tooth	Follicular
9	15	M	Left second premolar to right canine	Multilocular	Follicular
10	12	F	Left lateral incisor area	Unilocular	Plexiform
11	13	F	Right second premolar to right condyle	Unilocular	Plexiform
12	14	M	Left central incisor to right second premolar	Multilocular	Follicular
13	11	F	Right lateral incisor to left first molar	Multilocular	Follicular
14	15	M	Right lateral incisor to left first premolar	Multilocular	Plexiform
15	13	F	Left lateral incisor to right first premolar	Multilocular	Follicular
16	16	M	Left central incisor to right first premolar	Multilocular	Plexiform
17	14	F	Left canine to left angle	Unilocular with embedded tooth	Plexiform
18	18	M	Right first molar to right TMJ	Multilocular	Plexiform
19	16	M	Right canine to left first molar	Multilocular	Follicular

## DISCUSSION

Ameloblastoma occur in all parts of the world, however, the incidence varies in different populations. Ameloblastoma in children and young adolescents is not a frequent occurrence when compared with adults.<sup>10</sup> The overall rate of 16.8% found in patients < 18 years old in the present study is comparable with the findings of most authors from Africa<sup>7,8</sup> but on a higher side when compared with reports from among Caucasians.<sup>11,12</sup> In support of previous studies<sup>3,8</sup>, the tumour was more prevalent in males in this series; male-to-female ratio was 2:1.

Ameloblastoma at all age group is known to have a predilection for the mandible.<sup>11,12</sup> This is corroborated by our findings with 18 out of the 19 cases in this study found in the mandible. The distribution of ameloblastoma in the mandible however has been reported to vary in different races. In adult Caucasians, more than 70% of ameloblastoma are located in the molar and

coronoid process region (vertical ramus), in contrast to the findings in adult African and Asian populations, where majority of this tumour are found in the anterior part of the mandible.<sup>11,13,14</sup> Similar to the findings in adult Africans, 50% of the ameloblastoma in this report were located in the mandibular symphyseal region. Ord *et al*<sup>15</sup> also reported a preponderance of ameloblastoma located in the anterior mandible of African children. Although very little is known about the etiology of ameloblastoma, some authors have related the high incidence of this tumour in the anterior mandibular region to poor oral hygiene and irritation due to calculus deposit in this site.<sup>6,7</sup>

Previous reports<sup>16,18</sup> of ameloblastoma of the jaws from developing countries have shown that the lesions in the adults were usually gigantic on presentation, often associated with severe facial disfigurement. Surprisingly, this was also the observation in most of the young patients in this study (Figs 1 and 2). Because this tumour is known to be a slow growing neoplasm<sup>17</sup>, the late presentation of most of the patients, as observed in this study was most likely to be responsible for the big size of the tumours on presentation. Adekeye<sup>17</sup> attributed this delay in presentation to ignorance, inability to afford cost of treatment and the belief in seeking treatment first from the traditional healers, as was the common practise in most developing countries. The extensive size of the tumours was observed to negatively influence the postoperative morbidity. This strengthens the need for more health education and public enlightenment on the importance of early hospital attendance in this environment.

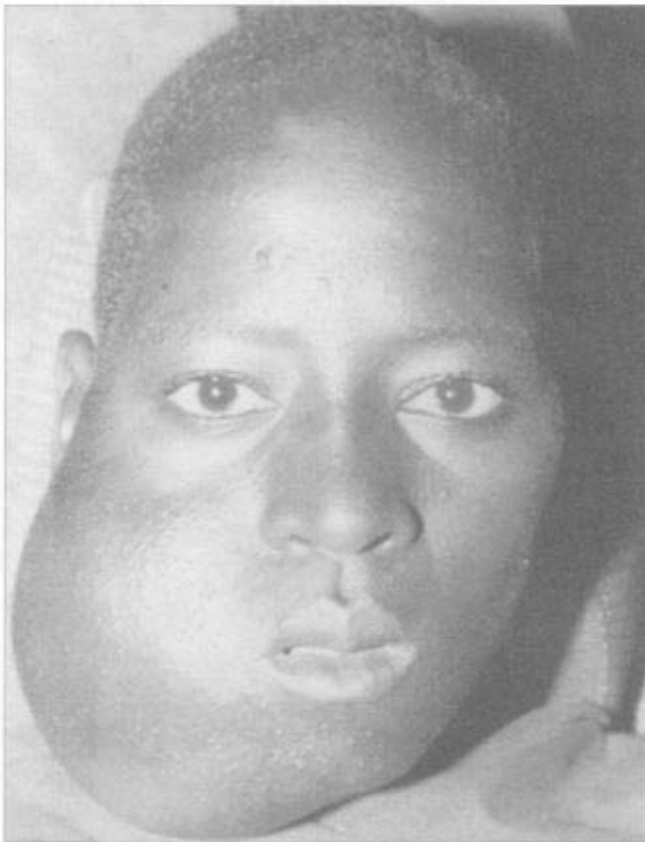


Fig 1: Photograph of a 15 year old boy with massive swelling of the lower jaw due to ameloblastoma.

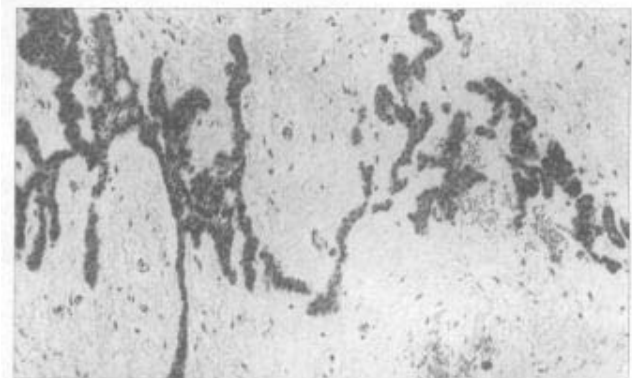


Fig 2: Photomicrograph showing the ameloblastoma in fig 1.

Although the prognostic value of the radiographic and histologic types of ameloblastoma is still in doubt<sup>11,13</sup>, some studies suggest that the biologic behaviour of this tumour may be related to both the radiographic and histologic appearance.<sup>12,19</sup> The most common radiographic appearance in the present study is the multilocular type (73.3%), a figure comparable with the findings in most African adults<sup>18,20</sup> but higher than the figure reported for young Jordanians<sup>21</sup> and young Western adolescents.<sup>22</sup> Ueno *et al*<sup>19</sup> in a study indicated that the most recurrent ameloblastoma were of the follicular type that radiographically had a multilocular or soap bubble appearance. Only 7 of the cases in this report were of the follicular type, however 6 out of these had a multilocular radiological appearance.

In adults, wide resection of the jaw is usually the recommended treatment for ameloblastoma, should priority be given to the recurrence rate.<sup>11,14,17</sup> The treatment of ameloblastoma in children and young adolescents, however, is still not well established and controversial.<sup>23</sup> In advanced cases of ameloblastoma in this series, where the inferior border of the mandible was involved, the method of treatment was radical resection. In cases, where the tumour did not affect the inferior border of the mandible, resection of the tumour with the dento- alveolar structures and preservation of the uninvolved inferior border was our treatment of choice. Conservative treatment of ameloblastoma in young patients is currently gaining wide acceptance in the literature especially for the unicystic variant.<sup>22,23</sup> Only two cases of unicystic ameloblastoma were seen in the present report. Unicystic ameloblastoma has been reported to be more common in Western children than African children.<sup>15,24</sup> Conservative treatments was not carried out in most of the patients in this series because of the massive and extensive size of most of the tumours at presentation.

Because of the limited facilities in our centre, it was not possible to carry out immediate bone grafting after tumour resection. Metallic implants were inserted and mainly used to provide support for the anterior floor of the mouth and the tongue muscles in cases where the anterior portion of the mandible had been resected. The implants also maintained the remaining mandibular fragments in a near normal rela-

tionship to each other. Infection was responsible for the metallic implants that dehiscd through the skin or the mucosa, however, the infections were controlled when the implants were removed and patients placed on appropriate antibiotics.

Three recurrent cases were treated by segmental resection and the single case that recurred following enucleation was treated by marginal jaw resection. Long time follow-up subsequent to resection of ameloblastoma cannot be overemphasized, as recurrences have been reported after 25 and 30 years of apparent cure.<sup>14</sup>

## CONCLUSION

Ameloblastoma is relatively rare in young Nigerians. The clinical features, radiographic and histologic patterns of ameloblastoma in the young in this population, however, appear to resemble that of adults. Since majority of the patients in this study presented with massive and extensive tumours, treatment in most cases was by wide surgical resection 1 cm into what appeared to be normal bone.

## REFERENCES

- 1 Sehdev MK, Huvos AG, Strong EW, Gerold FP *et al*. Ameloblastoma of the maxilla and mandible. *Cancer* 1974, 33:324-333.
- 2 Sawyer DR, Mosadomi A, Page DG, Svirsky JA *et al*. Racial predilection of ameloblastoma? A probable answer from Lagos (Nigeria) and Richmond, Virginia (USA). *J Oral Med* 1985,40: 27-31.
- 3 Chidzonga MM. Ameloblastoma in children. The Zimbabwean experience. *Oral Surg Oral Med Oral Pathol Oral Radiol Endod* 1996, 81: 168-170.
- 4 Olosoji HO, Enwere NO. Treatment of ameloblastoma- A review. *Nig J Med* 2003,12: 7-10.
- 5 Olaitan AA, Adekeye EO. Clinical features and management of ameloblastoma of the mandible in children and adolescents. *Br J Oral Maxillofac Surg* 1996, 34: 248-251.
- 6 Olosoji HO, Nggada HA, Tahir AA. Recurrence of solid multicystic Ameloblastoma. *Trop Doc* 2004, 34: 112-114.
- 7 Chidzonga MM. Ameloblastoma in children. The Zimbabwean experience. *Oral Surg Oral Med Oral Pathol Oral Radiol Endod* 1996, 81: 168-170.
- 8 Olaitan AA, Adekeye EO. Clinical features and management of ameloblastoma of the mandible in children and adolescents. *Br J Oral Maxillofac Surg* 1996, 34:248-251.
- 9 Kramer IRH, Pinborg J, Shear M. WHO Histological Typing of Odontogenic Tumours. 2<sup>d</sup> edition. Geneva. Springer-Verlag: 1992.

- 10 Odukoya OO. Odontogenic tumours: analysis of 289 Nigerian cases. *J Oral Pathol Med* 1995, 24: 454-457.
- 11 Mallick JA, Ali SA. Ameloblastoma- management and review of literature. *J Pak Med Assoc* 2002, 52: 488-490.
- 12 Janquera L, Ascani G, Vicente JC, Garcia-Consuegra L *et al*. Ameloblastoma revisited. *Ann Otol Rhinol Laryngol* 2003, 112: 1034-1039. Waldron CA, El-Morfty SK. A histopathologic study of 116 ameloblastoma with special reference to dermoplastic variant. *Oral Surg Oral Med Oral Pathol oral Med* 1987, 63: 441-450.
- 13 Waldron CA, El-Morfty SK. A histopathologic study of 116 ameloblastoma with special reference to dermoplastic variant. *Oral Surg Oral Med Oral Pathol Oral Med* 1987, 63: 441-450.
- 14 Olaitan AA, Arole G, Adekeye EO. Recurrent ameloblastoma of the jaws. A follow-up study. *Int J Maxillofac Surg* 1998,27: 456-460.
- 15 Ord RA, Blanchaert RH, Nikitakis NG, Sauk JJ. Ameloblastoma in children. *J Oral Maxillofac Surg* 2002,7: 762-770.
- 16 Akinosi JO, Williams AO. Ameloblastoma in Ibadan, Nigeria. *Oral Surg* 1969, 27: 257-265.
- 17 Adekeye EO. Ameloblastoma of the jaws: a survey of 109 Nigerian patients. *J Oral Maxillofac Surg* 1980,38: 36-41.
- 18 Simon EN, Stoelinga PJ, Vuhahula E, Ngassapa D. Odontogenic tumours and tumour-like lesion in Tanzania. *East Afr Med J* 2002, 79: 3-7.
- 19 Ueno S, Mushimoto K, Shirasu R. Prognostic evaluation of ameloblastoma bases on histologic and radiographic typing. *J Oral Maxillofac* 1989, 47: 11-15.
- 20 Lagundoye SB, Akinosi JO, Obisesan AA, Oluwasami JO: Radiologic features of ameloblastoma in Nigerians. *Oral Surg* 1975,39: 967-975.
- 21 Al-Khateeb T, Ababneh KT. Ameloblastoma in young Jordanians: a review of the clinicopathologic features and treatment of 10 cases. *J Oral Maxillofac Surg* 2003, 1:13-18.
- 22 Gardner DG, Anthony MJ. Treatment of ameloblastoma based on pathologic and anatomic principles. *Cancer* 1980,46: 2512-2519.
- 23 Tanaka N, Murata A, Yamaguchi A, Kohama G. Clinical features and management of oral and maxillofacial tumours in children. *Oral Surg Oral Med Oral Pathol Oral Radiol Endod* 1999, 1: 11-15.
- 24 Ajayi OF, Ladeinde AL, Adeyemo WL, Ogunlewe MO. Odontogenic tumours in Nigerian children and adolescents- a retrospective study of 92 cases. *World J Surg Oncol* 2004, 27: 39.