

## DIGITAL INTRA-ORAL RADIOLOGY: AN OVERVIEW OF THE CURRENT DIGITAL RADIOGRAPHIC TECHNOLOGIES AND AUTHOR'S PERSONAL EXPERIENCE WITH SCHICK'S CDR SYSTEM

\*MUNIR AHMAD, BDS, MSc (UK), Canadian Board Certified Dentist

### ABSTRACT

*Digital imaging is a revolutionary radiographic technology. The era of digital imaging in dentistry has certainly commenced. The aim of this article is to bring the dentists "up to date" with digital intra-oral radiographic system and discuss its present and future applications.*

*In this article an attempt has been made to enhance the awareness of dentists as regards to the benefits of digital intra-oral radiology. This will give an insight into the application, interpretation, results and the tremendous progress of this latest technology.*

*This article also includes the personal experience of the author with Schick's CDR that the author has been using since 1994. A comparison has also been made between various systems available in the market.*

**Key words:** *Digital Radiology, Digital Imaging, Radiographic Technologies, Benefits of Intra-oral Radiology, Interpretation, Schick's CDR, Digital Systems.*

---

### INTRODUCTION

Direct digital intra-oral radiographic systems have shown tremendous progress in the past few years. Several systems for the acquisition of digital images are now available in the market.

The direct digital systems rationalize the radiographic routine due to significant dose reductions and the ability for image quality manipulation. The software required to archive, manipulate and retrieve the digital images are growing. Programs to improve the diagnostic yield of digital imaging are becoming more sophisticated and will be of great help in general and specialized dental diagnosis. Digital radiology will have a substantial impact on present and future dentistry.

Since its introduction, the digital intra-oral radiography has been the subject of much clinical research. Investigators have reported on the efficacy of this technology in detecting the proximal and the occlusal

carious lesions, assessing the root canal length and the periodontal lesions.

New systems are emerging rapidly on the market and it is important that the dentist should recognize the advantages and disadvantages of these systems by comparison with the X-ray film.

Most of the digital intra-oral radiography systems available in the market are based on the same basic principles and are quite similar in the manner in which the images are manipulated, stored, retrieved and transmitted. They all use the available computer technology and all of them share a common goal that is the less radiation and an increased clinical efficiency.

With this film-less intra-oral system, the dentist can take the X-ray pictures and within few seconds display the image in a large format on a computer screen. The direct digital dental imaging system, based on a sensor with a special charged-coupled device

---

\* Dr Munir Ahmad, Dr M Ahmad Dentistry Professional Corporation, Address #1: Dixie Park Centre, 1550 South Gateway Road, Suite 333, Mississauga, ON, L4W 5G6, CANADA. Address # 2: 2304 Islington Ave., Suite 203, Toronto, ON, M9W 3W9, CANADA, (E.[mail: munirahmad@on.aibn.com](mailto:munirahmad@on.aibn.com))

(CCD), is designed especially for the direct exposure to the X- radiation, using the conventional X-ray unit with an electronic timer and a personal computer platform with the dedicated peripherals.

Application software is installed that manages the operation of the sensor (the exposure, capture, storage, and the enhancement of the images) and provides a user interface specifically conceived for real time imaging. The X- ray images can be manipulated electronically to change the contrast, resolution, brightness, noise reduction, edge enhancement, pseudo-colour, orientation and the size of an image. Measurements can be made electronically which is an invaluable asset in endodontics. The local magnification, zoom, rotation, mirroring, and the measurement of the angles are also available.

The images are stored in patient files in the computer. An external optical mass storage device is used for the permanent storage of the images in the digital format. A printer may be used to create hard copies.

If the selected exposure is incorrect, the error is apparent immediately and can be adjusted before further exposures are made. No more darkroom, chemistry, processor, film or waiting is required.

It is possible to display several images at one time on the screen, allowing the comparison of the new images with the previously stored images, in the same file number.

Currently, a variety of CCD based intra-oral radiographic systems are available in the market including the CDR (Schick Technologies), DEXIS Digital X-Ray, DIXI2 (Planmeca), RVGui (TREX trophy), IMAGE RAY (Dentrix), IMAGE RAY and SUNI.

## COMPONENTS OF DIRECT DIGITAL IMAGING SYSTEM

The basic components of the majority of the direct intra-oral digital radiography systems incorporate: (Figs 1, 2)

- 1 **Intra-Oral Sensor** (a charge-coupled device)
- 2 **Display Processing Unit** (Interface, Data Transmission Module)
- 3 **Software**
- 4 **Personal Computer** (desk top or Laptop)




Fig 1: Sensor, Interface and USB cable to connect to a Desk top or Laptop




Fig 2: Three sizes of sensors, # 0,1 & 2 comparable to film sizes are available

## TECHNIQUE OF ACQUIRING INTRA-ORAL DIGITAL IMAGES

The direct digital dental imaging involves the placement of a sensor in the patient's mouth and a conventional x-ray unit is used to expose the sensor to the radiation. The patient is exposed to the radiation as before, but because of the sensitivity of the sensor, the dosage necessary to produce a radiographic image is reduced by 80 to 90 % compared to the dosage required by a conventional X-ray film<sup>1</sup>. The resultant image is immediately produced and displayed on a computer screen.

Following is the general technique used in obtaining the digital dental images.

### Setup

- A custom radiographic series on the computer screen is selected and the patient information is entered in the computer. (Fig 3)




Fig 3: Shows a full mouth series selected and patient's information has been entered.

- The sensor (already cold sterilized) is covered with a disposable sterile sheath and is placed in the holder.
- The sensor is positioned in patient's mouth.

**Sensor Positioning**

All intra-oral digital radiography systems use the same projection techniques (using the positioning devices) as film-based radiography<sup>2</sup> (Fig 4).



Fig 4: Positioning devices (Holders, Arm, & Rings)

**Periapical Projection (PA)**

**For Posterior Teeth** (Figure 5)

- The sensor is placed in the Posterior Periapical holder and positioned into the mouth horizontally

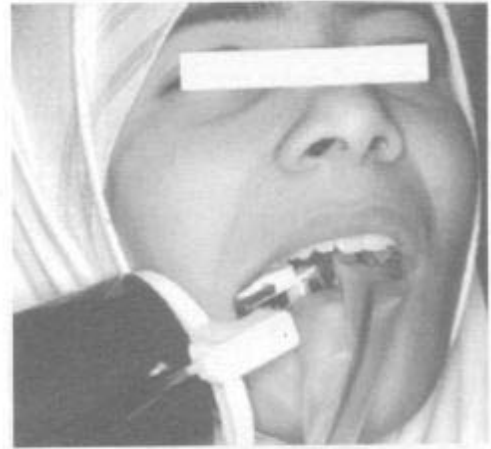

Fig 5: Sensor with posterior holder is placed in Right Man. Molar region. Cone of X-ray machine is positioned on the aiming ring

and rotated into position well palatal/Lingual to the tooth surfaces.

- For the Maxillary Molar region, the sensor should be placed across the midline of the palate and for the Mandibular Molar projection, it is kept parallel to the occlusal plane, while requesting the patient to take the tongue to the opposite side.

**For Anterior Teeth** (Figure 6)

- The sensor is positioned in an anterior holder and placed vertically well into the mouth.

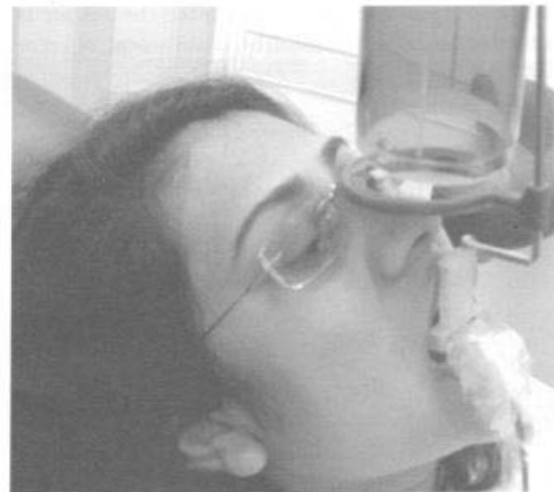

Fig 6: Anterior holder with sensor placed to take PA of upper incisors

## Bite-wings (Fig 7)

- For bitewings of molar region, the sensor is placed in a bitewing holder and positioned parallel to the molars. For premolar bitewings, the sensor is placed diagonally, with the anterior portion between the incisors.

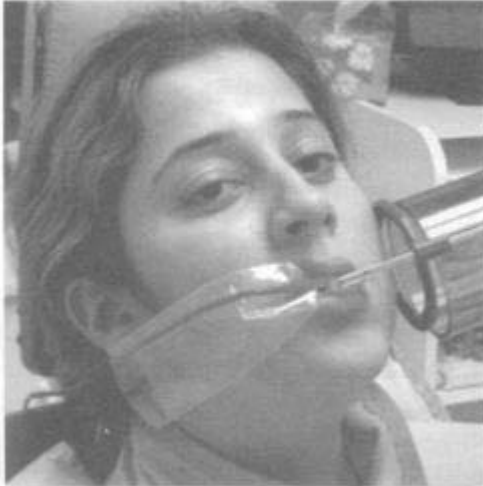

Fig 7: Sensor in Bite Wing Holder

## Exposure

The next step is to set the X-ray machine as recommended by the manufacturer of the digital system (set at approximately one-tenth of the D-speed film setting); 0.06 second (three impulses), for the molars. It takes approximately five to seven seconds for the image to appear on the screen after the sensor is activated and after that the dentist can accept, reject or retake the X-ray. The image is automatically saved in the hard disk.

During the exposure, the sensor reacts to the X-ray emission and the image data is integrated as electrical charges in the sensor. Immediately after the exposure, charges (collection of electrons) on the sensor are translated to the digital data by a circuit board and transferred to the computer where the image is displayed on a monitor.

## CURRENT OPINION

Eventually, the film-less and paper-less patient record will be based on the digital radiographs, intraoral video images, the digital dental tomograms (OPG; PAN) and the computer-based dental charts including

all the diagnostic, the treatment, and the financial records of the dental practice<sup>3</sup>.

The cost of the system must be compared to the savings in the film, the chemicals, and the disposal of radiographic wastes. For the new practice it also saves on the purchase of an automatic processor and dark-room costs. The value of the time savings is dependent on the opportunity cost gain in the usage of the saved time.

The instant chair side viewing of radiographic images on a monitor screen means that the patient and dentist can simultaneously view and discuss the patient's oral condition as revealed by the images. In this capacity, the digital dental radiography serves as an excellent educational and communicative tool by allowing the patients to participate in their diagnosis and treatment planning.

## INTERPRETATION OF DIGITAL IMAGING IN DENTAL RADIOLOGY

Mol and Van der Stelt<sup>4</sup> have applied the computer programs for the assessment of the periapical bone defects. Computer-aided methods have also been developed for the recognition of the periapical area by Orstavik<sup>5</sup>.

Heaven *et al.*<sup>6</sup> have reported on the development of a computer software for an automatic detection and the measurement of the proximal caries lesions on the digital images.

Wagner *et al.*' have developed an image and rule-based decision support system, employing the computer-based technology to assist dentists with the radiographic interpretation.

## ADVANTAGES AND DISADVANTAGES

### Advantages

Direct digital dental radiology has several benefits over the film based systems.<sup>8,12,13</sup> This allows the immediate production of an image, expediting treatment such as root canal fillings and the procedures of the placement of the dental implants. Many specialists including Periodontists and Implantologists find this technique very useful as they can quickly take inter-operative images while preparing the operative site. Moreover, during the active treatment,

the digital intra-oral radiography has found its best application.

There are many articles and publications that describe the wide array of advantages of digital imaging.<sup>9,11</sup>

Another advantage of a film-free system is the elimination of the time-consuming darkroom procedure that often fails to produce high quality radiographs. Undoubtedly, a major reason for the low quality often found in current dental radiography is the faulty darkroom procedure. Digital intra-oral radiography eliminates the darkroom, films, and cassettes, intensifying screens, processors, a water supply and the processing solutions. Dentists can get rid of their stores of the X-ray film and simply store the images on the computer hard disk.

The sensitivity of the sensors and the digital nature of the image permit the reduction of the patients' radiation dose. The percentage of the radiation reduction, compared with the E-speed film, ranges from 80 percent to 90 percent, depending upon the system, the sensor and the X-ray generator.

The slowest digital system takes seven seconds while an automatic processing takes four minutes.

### Disadvantages

Disadvantages of the digital dental radiography include the initial cost of the system, and some difficulty in placing the sensor with the holder in the third molar region.

### AUTHORS EXPERIENCE WITH CDR

This scribe is using the Schick CDR for more than eleven years. We have found digital system very useful.

The author developed a simple technique that helps in reducing the discomfort to the patient during placement of sensor holders for taking PA, BW and FMX (Full Mouth X-Rays).

Our personal experience with CDR system suggests that if the size 2 of the sensor is positioned accurately in the mouth, it covers a reasonable area of interest due to its size that approximates the size of 2 films. Sensor placement is the "art" in digital radiogra-




Fig 8: Full Mouth X-Rays recorded in the patient's file and displayed on the Computer

phy and is the most important part of acquiring a reasonable digital image that could then be interpreted adequately. Therefore, if an adequate coverage with proper positioning and projection is obtained, the interpretation of the digital image should not be a great concern for the dentist, provided he/she has sufficient knowledge of interpreting a radiograph.

### Clinical trials

We have acquired more than 10000 Digital X-ray images and carried out some clinical trials with the CDR using it's size 2 sensor. Some of the results are shown in Figures 9 to 18. An example of well coverage of Mandibular third molar by the Sensor is shown in

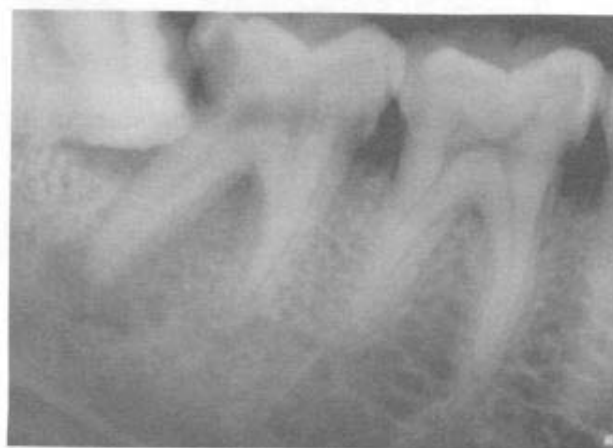

Fig 9: Sensor has covered well beyond the Roots of Molars. MA Impaction has caused distal decay with large PA radiolucency in Rt. Man. Second Molar

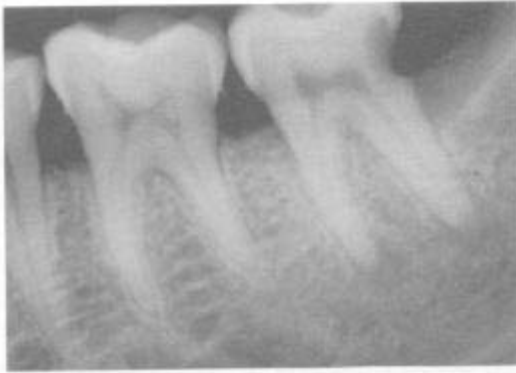

Fig 10: Left. Mand. Second Molar reveals distal decay with PA radiolucency

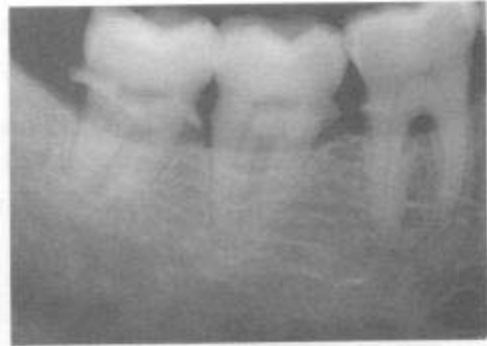

Fig 14: Subgingival calculus and bone loss

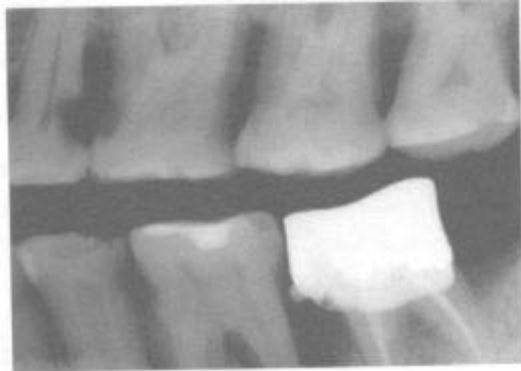

Fig 11: Bitewing of left posterior region showing poorly fabricated crown left Man. Second Molar

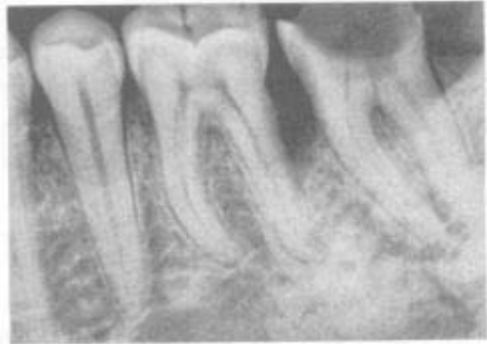

Fig 15: Grossly decayed Left Second Man. Molar with Vertical bone loss

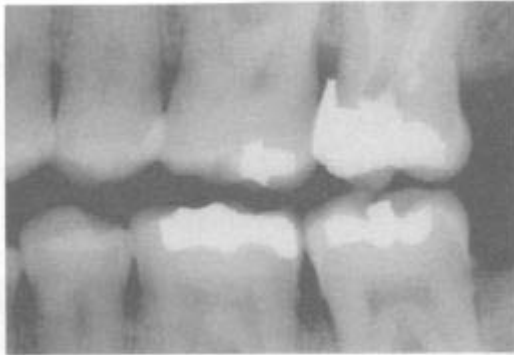


Fig 12: B.W shows overhang amalgam restoration in left Max Second Molar

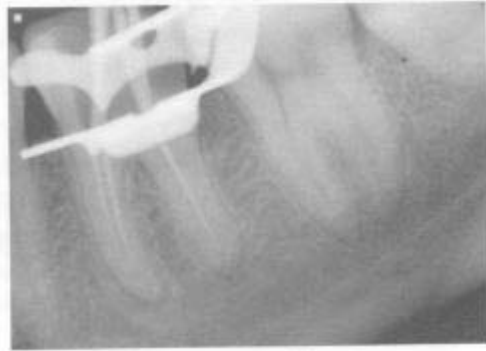

Fig 16: Endo in progress. Incomplete obturation in Mesial roots (2mm short) is noticed. RD clamp is also seen

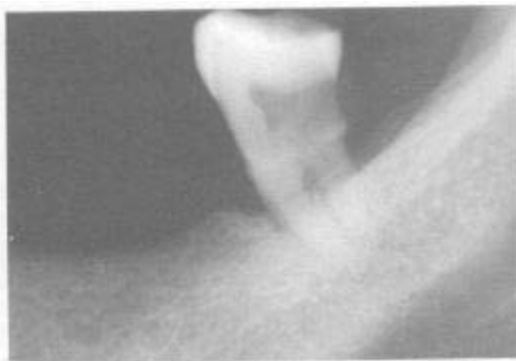


Fig 13: Severe bone loss

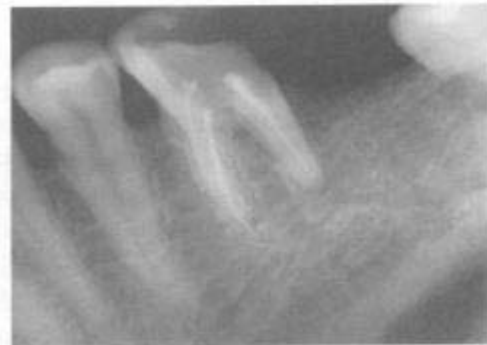

Fig 17: Failed Endo. Gutta Percha seen 2mm beyond the apex in left Man. First Molar

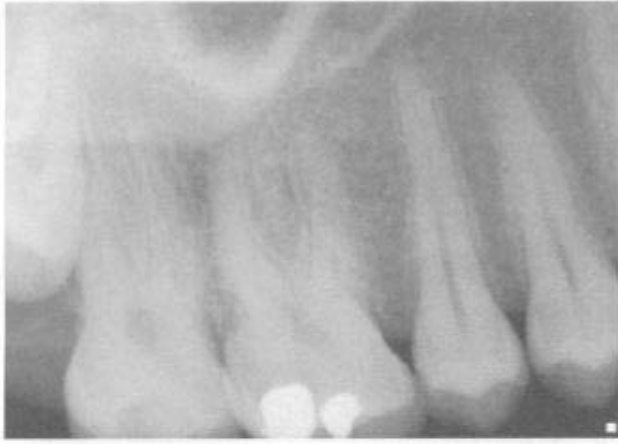

Fig 18: Well placed Sensor, image showing crown and apex of Right Max Post Teeth. Shadow of Mylar bone is well above the apex of Molar

Figure 9 where gross decay at the distal aspect of the second molar is visible. A well defined, large periapical radiolucency associated with distal root extending towards inferior alveolar canal is also noticed in this view. For obtaining this PA projection, the sensor was kept as deep as possible in the mandibular posterior region.

In another case, the patient was suffering from dull pain in the left mandibular region. Figure 10 shows a PA that revealed distal decay with PA radiolucency associated with mesial & distal roots in second molar.

Figure 11 shows a bitewing of left posterior region. Poorly fabricated crown with overhanging margins are clearly seen in left mandibular molar. Severe generalized bone loss and root caries in maxillary second premolar and first molar is also seen.

From our experience with the CDR system, we are convinced that this system can produce clinically acceptable images that are comparable to the film.

Schick technologies claim that 400,000 exposures can be made with the CDR sensor without any damage.

### **X-ray machine**

We are using the Belmont 066 X-ray machine operating at 60 kVp, 10 mA. To obtain the images using the CDR system, we have set it's electronic timer to 315 milliseconds which is the lowest possible setting for the exposure in this machine.

It is recommended that if the images acquired at the lowest possible exposure time appear to be overexposed and if it is not possible to decrease the setting further, then the X-ray source should be kept further away from the sensor with the help of a longer cone.

### **OTHER X-RAYS OF CLINICAL INTEREST ACQUIRED BY US USING THE DIGITAL SYSTEM (Figs 12 to 18)**

#### **• SOFTWARE FUNCTIONS**

##### **Measurement of the distance (Fig 19)**

Between two points on the image, the distance can be measured as a Straight Line, or the Multiple Lines. The distance is displayed in the upper left side of the screen.

An angle between the two lines can be displayed as shown in Fig 19.

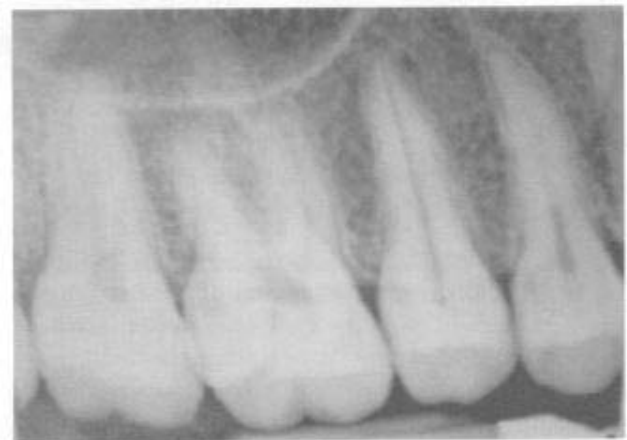

Fig 19: A line is drawn for measuring the canal length

Due to the angulations of the sensor and variations in the distance to the X-ray machine, there may be a distortion in the on-screen distance measurements. This can be corrected by using the 'Calibration' function by placing an item of known length (such as an endodontic file) in the area being X-rayed and calibrating the distances to that measurement.

##### **Zoom (Fig 20)**

The Zoom function is used in the exam window to evaluate all the images in an exam. Zoomed view of the entire series can be obtained by panning from image to image.




Fig 20: Zoomed image in Full mouth series Grid (**Fig 21**)

To reflect the linear calibration, a 1mm x 1mm grid is used on top of the image.

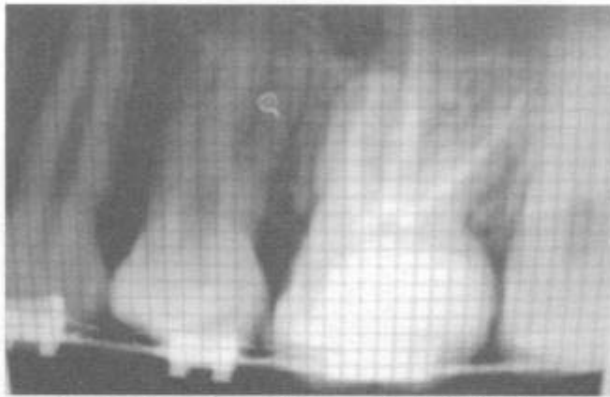


Fig 21: Measuring distances by Grid Pattern

**Flashlight (Fig 22 a, b)**

Flashlight is selected to enhance the contrast of the image. Other enhancement features can be used, including: Positive, Sharpen, Spot Remover, and Equalize from the Enhance menu, and Maximize

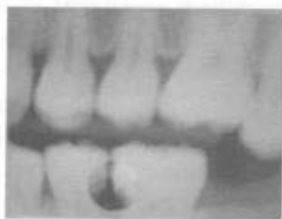

Fig 22 a:

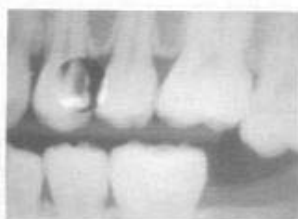

Fig 22 b: Flash Light showing proximal decay which is not clear in Fig 22 a

Contrast (default), Darken, Lighten, and Normal from the Contrast menu.

**Image Reorientation**

The images can be rotated to 180 degrees and can also flip them upside down and left to right.

**Swap Views**

Any two images can be swapped, regardless of their orientation.

**Equalization**

This function makes the light image dark, that is, the darkest pixels will be made all black by stretching the contrast of an image.

**Contrast (Fig 23)**

The brightness and the contrast of an image may be altered by controlling the scroll bars to the right of the tool bar.

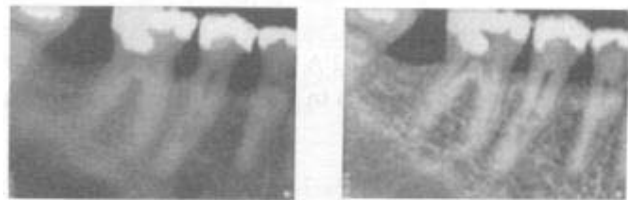


Fig. 23: Before Revealer

After Revealer

**Density Measurements**

**Pixel Value**

The grey value of any pixel on the image can be found by using 'Pixel Value' command. The Pixel value is shown as a percentage and is used to find out the relative bone and tissue densities. If the pixel value is lower, this means that fewer X-rays have passed through to the sensor and the density is measured as 'high'.

**Histogram (Fig 24)**

This function also measures the pixel value on the image. Histogram can be generated as the Horizontal, the Vertical and the Line. For the Horizontal Histogram, each pixel on the row chosen on the image will be measured and represented graphically that superimposes on the image. The graph will be higher if the grey value is higher that represents the lower density.

**Notes**

The notes may be added to each image. A numbered flag is placed on the image and the text.



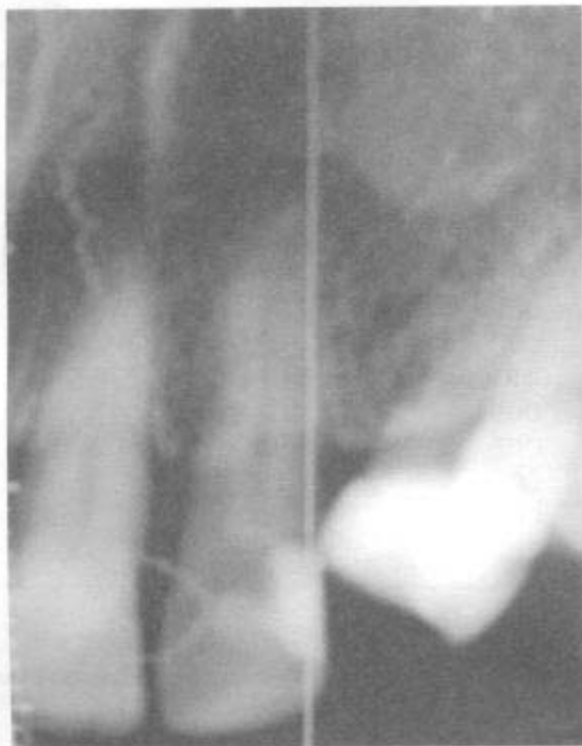

Fig. 24: Vertical Histogram

### Viewing Multiple Images

Two or more images can be viewed from one exam or more exams and all the images of a particular tooth can be viewed by using the 'X-ray History' function.

### Enhanced Features

The inverse grey shade image may be shown as positive, the fixed pattern noise in the image can be removed by using the 'Spot remover' function and the image can be sharpened by passing through a filter that accentuates edges in the image whereas a pseudo colour image is produced by using the dates of examination.

### COMMUNICATION AND TELERADIOLOGY

Quick progress has taken place in the tele-communications and the tele-radiology. The data interchange with the help of the computer networks is increasing since its operation started at the beginning of 1992.

### SIGNIFICANCE OF TRANSMITTING DENTAL IMAGES

The objectives of transmitting the images are:

- For obtaining the specialists' advice on the diagnosis and the treatment planning and for the second opinion, specially within under-developed parts of the world.

- For the real-time interaction between the clinicians and the third party carriers for treatment permission and for the confirmation of services provided.
- Forensic identification. The image transmission accelerates the investigation by the forensic dentist.

### SELECTION OF A DIGITAL DENTAL SYSTEM

It is important that before selecting a digital dental system, the dentist should do some planning and clearly identify how they intend to use the equipment. They should first decide their general and particular requirements, and then compare the different systems to determine which has the characteristics best suited for their type of practice.<sup>14</sup> There is no doubt that such technology can save time and money in the long run and may also be useful from other aspects provided that the dentist has some realistic expectation from the system.

It will be useful if the user makes a rough calculation of the number of images one will take per day before buying a system. To make an estimate of this, suppose one takes 6 images daily, multiplying it by 100 will give an upper limit of 600 megabytes that will be the yearly storage requirement.<sup>9,10</sup>

One should also consult the current users of the system to find out their satisfaction with the product. Also it is important to check whether the existing X-ray generator is compatible with or can be modified to work with the system.

### Product support

Almost all the manufactures provide the product support including the software updates free of charge during the first year. It is always reassuring to know that the development does not stand still.

### COMPARISON OF VARIOUS SYSTEMS

It may be noticed that the difference between the various digital intra-oral radiographic systems is not great in terms of the usage of the computer technology, the acquisition of the images and the reduction of the radiation dose.

The comparison of Approximate Costs, Device Type and Connection of Digital Imaging Systems are shown in table 1.

TABLE 1: COMPARISON OF APPROXIMATE COSTS, DEVICE TYPE AND CONNECTION OF DIGITAL IMAGING SYSTEMS

COMPANY	SENSOR NAME	DEVICE TYPE	CONNECTION	COST
SCHICK	CDR	CMOS	USB	\$12,000
TECHNOLOGIES	GX-S	CCD	USB	\$11,000
DENTSPLY GENDEX	INTRAORAL			
CYGNUS	CYGNUS RAY	CCD	USB	\$11,000
DEXIS	DEXIS	CCD	PCMCIA	\$9,995
INSTRUMENTARIUM IMAGING	SIGMA	CCD	USB	\$8,995
SIRONA USA	SIDEXIS	CCD	PCI/ETH ERNET	\$8,500
LIGHT YEAR	LIGHT YEAR	CMOS	USB	\$8,495
PLANMECA	DIXI2	CCD	PCI AND USB	\$5,600
DENTRIX	IMAGERAY	CCD	USB	\$6,995
SUNI	SUNI	CCD	USB	\$5,495
DENT-X EVA	EVA	CCD	USB	\$4,995
TREX TROPHY	RVGUI	CCD	PCI	\$6,995

## CONCLUSION

The future of dental imaging may well rest with the digital image acquisition. The perception of detail that now is necessary for the diagnosis may no longer be required in the near future. More computer software programs are being developed that recognize, describe and categorize the pathologic changes in teeth and jaws.

Besides the direct digital radiographic systems, the dental imaging has developed to add the DPT (Dental Panoramic Tomogram; OPG; PAN) and the video while work is progressing on the optical impressions and the three-dimensional radiography, all of which have common image processing needs.

Possibly the most attractive future for the imaging is its entry into the cyberspace, including the virtual reality that relies on the digital acquisition of the images. It will mix the interaction and the sound to help clinicians in reaching the diagnoses and doing trial Surgeries. For example, in a case of suspected tempromandibular joint dysfunction, a virtual reality system may enable the clinician not only to look at the joint complex in a static condition, but also to notice and hear the joint during the functional movement.

It should be essential on the part of curriculum of the conventional dental radiography for the undergraduate dental studies to include the direct digital intra-oral radiography. More emphasis should be put on the techniques and the interpretation of the digital systems. The development of the training programs for the beginners and the users will emphasize the value of the digital dental radiography and minimize its limitations.

## REFERENCES

- 1 Razzano MR and Bonner P. RadioVisioGraphy: Video Imaging Alters Traditional Approach to Radiography. *Compend Contin Educ Dent.* 1990 June. 6(6)398-400
- 2 Van Der Stelt PF. Improved Diagnosis with digital radiography. *Orthodontics and Pedodontics* 1992, 2(4): 1-6.
- 3 Farman AG, Digital Imaging in Cranio mandibular Practice. *Cranio.* Guest Editorial. July 1993 July. 11( 3 ) 161-163.
- 4 Mol A, Van der Stelt PF. Application of digital image analysis in dental radiography for the description of periapical bone lesions. *IEEE Trans on Biomed Eng.* 1991; 38:357-359.
- 5 Orstavik D. Radiographic evaluation of apical periodontitis and endodontic treatment results: a computer approach. *Int Dent J.* 1991;41:89-98.
- 6 Heaven TJ, Firestone AR, Feagin FF. Computer- based image analysis of natural approximal caries on radiographic films. *J. Dent Res.* 1992; 71:846-849.
- 7 Wagner IV, Schneider W, White SC, van der Stelt PF. Image-and rule-based decision support for oral radiographic interpretation. (Proceedings of the Third Symposium on Digital Imaging in Dental Radiology, Noordwijkerhout, The Netherlands, 13 and 14 October, 1994) *Dentomaxillofac. Radiol.* 1995; May; 24(2):97-98.
- 8 Wallace JA, Nair MK, Colaco MF, et al. A comparative evaluation of the diagnostic efficacy of film and digital sensors for detection of simulated periapical lesions. *Oral Surg Oral Med Oral Pathol Oral Radiol Endod.* 2001 Jul; 92(1): 93-7.
- 9 Miles DA and Davis E. Electronic imaging in the dental office. *J Can Dent Assoc* 59(6):517-21, 1993.
- 10 Khademi J. Choosing digital radiography for the right reasons. *Dental Practice & Finance.* 1995 March / April. 43-49.
- 11 Paurazas SB, Geist, JR, Pink FE, et al. Comparison of diagnostic accuracy of digital imaging using CCD and CMOS-APS sensors with E-speed film in the detection of periapical bony lesions. *Oral Surg Oral Med Oral Pathol Oral Radiol Endod.* 2000 March;89(3): 356-62.
- 12 Frederiksen NL. Specialized radiographic techniques. In: Pharaoh MJ, White SC, editors. *Oral Radiology Principles and Interpretation.* 4th Edition. St. Louis, Mosby, 2000. p. 223-4.
- 13 Edwin TP, Digital Radiography: An Overview, *The Journal of Contemporary Dental Practice*, Volume 3, No. 4, November 15, 2002.
- 14 Miles DA, Digital X-ray Decision-making: Bringing It All Into Focus, *Going Digital: The Digital X-ray Guidebook to Success*, 2004.