

## PERIODONTAL APPROACH TO ESTHETIC DENTISTRY

<sup>1</sup>SHANKAR BABU

<sup>2</sup>KHUSHBU ADHIKARI

### ABSTRACT

*It is the responsibility of the dental team to understand optimal esthetics, the indications for treatment, and to be able to effectively communicate with the patient. Currently, periodontal surgery is considered to be of two components – Excisional periodontal surgery and Regenerative periodontal surgery. The former includes gingivectomy, flap surgery to eliminate pockets without using regenerative techniques and resective osseous surgery. The latter includes use of bone grafts, guided tissue regeneration, guided bone regeneration, root conditioning procedure and periodontal plastic surgery. This comprehensive review focuses on the various indications and procedures in periodontal esthetic surgeries.*

**Key Words:** Periodontal esthetic procedure, resective periodontal surgeries, regenerative esthetic surgeries. esthetic smile.

### INTRODUCTION

The word 'Aesthetics' is derived from 'Ästhetisch' (German) or 'Esthétique' (French). It means "the science which treats the conditions of sensuous perception". Today cosmetic concerns as well as increased intra-oral awareness have created a demand for esthetics in periodontal practice. Esthetic improvements are the primary indication for performing periodontal plastic and soft tissue reconstruction surgery. It is the responsibility of the dental team mainly periodontists to understand optimal esthetics, the indications for treatment, and to be able to effectively communicate with the patient. Modern dentistry not only provides us with better material and technology but ensures that today's procedures are performed with minimal discomfort and maximal safety.

"Mucogingival surgery" is a term that was initially introduced by Friedman; The Glossary of Periodontal terms defined Mucogingival surgery as – Periodontal surgical procedure designed to correct defects in the morphology, position and/or the amount of gingiva. This literature review focuses on Periodontal Plastic Surgery- its scope, limitations and esthetic implications in periodontal practice. This comprehensive review focuses the basic guidelines and need for the esthetic management taking into consideration the periodontal health.

**Corresponding Author:** <sup>1</sup>Dr Shankar Babu, TP MDS, Periodontist and Oral Implantologist New Abha Dental Specialty Center, Kuwait E-mail: dr\_shankartp@rediffmail.com

<sup>2</sup> Dr Khushbu Adhikari, MDS, Resident, Department of Periodontology and Oral Implantology, CODS, Universal College of Medical Sciences, Bhairahawa, Nepal E-mail: adhkhush@gmail.com

**Received for Publication:** November 29, 2014

**Revised:** January 19, 2015

**Accepted:** February 7, 2015

### THE AESTHETIC SMILE

Until recently, a misconception prevailed among dentists and the general public that the concept of dental aesthetics was limited to alteration in teeth alone. The dentist was forced to accept the pre existing relationship between teeth, gingival scaffold and the lips.<sup>1</sup> Any changes in the pre-existing "Lip-Gingival-tooth" relationship was thought to require orthodontic therapy in conjunction with orthognathic surgery or aggressive periodontal procedures.<sup>2</sup> However, with the advent of soft tissue plastic surgery, much of this has changed. The sphere of Periodontics has been upgraded from strictly being a health service to one which provides optimal aesthetics.

The essentials of a smile involve:

The teeth

The gingival scaffold

The lip framework<sup>3</sup>

**The teeth:** The color, position and the shape or silhouette form of the teeth are of importance. The advent of adhesive dentistry allows instantaneous and aesthetic change in color, position and shape of teeth using various bonding techniques such as laminate veneers and direct composite bonding.<sup>4</sup>

**The gingival scaffold:** Periodontal therapy is associated with restoring periodontal health and maintaining the integrity of the attachment apparatus<sup>5</sup>. But in today's practice, apart from being healthy, there should be a certain degree of harmony and continuity of the free gingival margin.<sup>6</sup>

**The lips:** The lip form frames the smile and defines the aesthetic zone.<sup>7</sup> Lip lines can be classified as high, medium or low, depending on relation of inferior border of lip with gingiva and teeth.<sup>8</sup>

- 1 High lipline – shows a large exposure of the gingiva extending from the inferior border of the upper lip to the free gingival margin.
- 2 Medium lipline – when the patient smiles, a nominal exposure of 1-3 mm of the gingiva from the apical extent of the free gingival margin to the inferior border of the upper lip is exposed.
- 3 Low lipline – only a portion of the teeth are exposed below the inferior border of the upper lip.

The teeth are exposed in their entirety as well as the interdental gingival tissue and the border of the free gingiva around the cervical area of the tooth.<sup>8</sup>

#### Horizontal and vertical reference lines of the face:

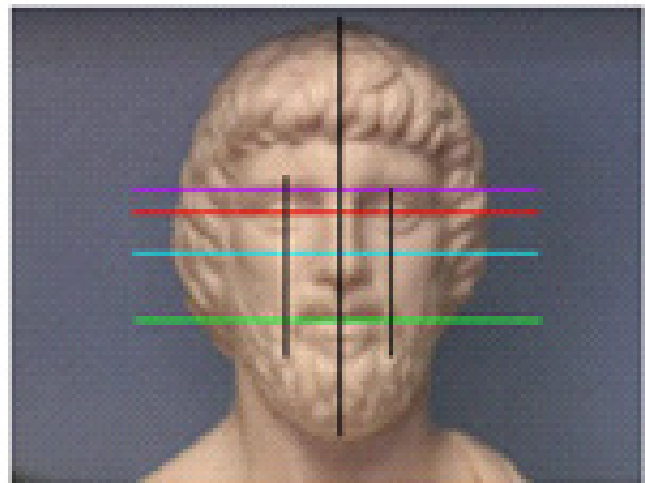
Most clinicians have the tendency to focus on the defect, but when evaluating aesthetic problems, the clinician needs to widen the focus, studying first the proportions of the face<sup>9</sup>, how these proportions relate to the smile and how the lip line relates to the teeth and the mucogingival complex.<sup>7</sup> The “perioaesthetic”<sup>10</sup> defect should then be evaluated. In an aesthetic analysis of the dentogingival complex, the midline of the face, the position of the incisal edges and the gingival line are important landmarks. The gingival line is defined as the tangent running through the height of contours of the maxillary central incisors and canines, ideally should be parallel to the bipupillary line and the incisal edges. Additionally, the papilla between the maxillary central incisors should coincide with the midline of the face.<sup>9</sup>

## PERIO-AESTHETIC PROCEDURES SURGICAL CROWN LENGTHENING FOR FUNCTION AND AESTHETICS

Crown lengthening involves the surgical removal of hard and soft periodontal tissues to gain supracrestal tooth length, allowing for clinical crowns and reestablishment of the biological width.<sup>12</sup> Crown lengthening has been described as a procedure similar to an apically repositioned flap with ostectomy/osteoplasty.<sup>13</sup> The lengthening procedure is indicated to provide tooth length for caries removal, restoration of the tooth without violating the biologic width, restoration retention and aesthetics.<sup>14</sup>

#### The biologic width

In 1961 Gargiulo et al studied human cadavers



- Vertical lines can be drawn from the pupil of the eye to the corners of the mouth
- The face can also be horizontally divided into thirds as can be seen by line.<sup>11</sup>

#### Root coverage techniques

Currently numerous surgical techniques are proposed for root coverage

1 Pedicle soft tissue grafts	2 Free soft tissue grafts	3 Additive treatments
A) Rotational flaps	A) Non-submerged graft	A) Root surface modification agents
- Laterally positioned flaps	- One stage (free gingival graft)	A) Enamel matrix proteins
- Double papilla flaps	- Two stage (free gingival graft + coronally positioned graft)	B) Guided tissue regeneration
B) Advanced flaps	B) Submerged graft	-Non-resorbable membrane barriers
- Coronally repositioned flap	- Connective tissue graft + laterally positioned flap	- Resorbable membrane barriers
- Semilunar flap	- Connective tissue graft + double papilla flap	
	- Connective tissue graft + coronally positioned graft (Subepithelial connective tissue graft)	
	- Envelope techniques	

sulcus or periodontal pocket. He noted a consistency in the dimension of the various components:

The average sulcus depth of 0.69mm: The average junctional epithelium of 0.97mm and the average supra alveolar connective tissue attachment of 1.07mm (range of 1.06-1.08mm).

The combined dimensions of the connective tissue attachment and junctional epithelium averages to 2.04mm this is called the "biologic width".<sup>15</sup> After invasion of this zone, a healthy situation will not continue; instead it will develop crestal bone loss, gingival recession, and or localized gingival hyperplasia.<sup>16</sup>

### **The gummy smile**

A gummy smile<sup>17</sup> or high lip line case can result from two basic problems – altered passive eruption and vertical maxillary excess.<sup>18</sup> One of the clinical criteria in determining which of these factors is responsible for a gummy smile relates to the basic shape of the teeth.<sup>19</sup> If teeth appear to be somewhat short and squat – vertical dimension appears too short as compared to the horizontal dimensions, the gummy smile is probably due to altered passive eruption.<sup>19</sup> If however the silhouette form of the tooth appears to be normal and an expanse of tissue is exposed below the inferior border of the upper lip, it is probably due to the overgrowth of the maxilla in a vertical dimension or vertical maxillary excess. In many cases a gummy smile is due to combination of these two factors.<sup>17,18</sup>

### **ROOT COVERAGE**

Role played by the attached gingiva in maintenance of gingival health is controversial.<sup>20</sup> It was originally believed that a minimum width of attached gingiva was required to maintain optimal gingival health and prevent recession.<sup>21</sup> It was demonstrated that with proper oral hygiene and absence of bacterial plaque and gingival health in the form of no attachment loss and absence of infection can exist with minimal or no attached gingiva.<sup>22</sup> Various longitudinal studies have demonstrated that the lack of or the presence of minimal amount of attached gingiva does not necessarily result in the progression of soft tissue recession.<sup>23</sup> Studies have also shown that a narrow zone of gingiva possess the same resistance to continuous attachment loss as the tooth with wide zone of attached gingiva.<sup>22</sup> Dorfman, Lang and Loe on the other hand suggested that a minimum width of 2mm of gingiva needs to be present for gingival health to exist.<sup>24,25</sup> Areas with 1mm or less of attached gingiva often presented with clinical signs of inflammation.<sup>22</sup> Gingival recession is defined as the location of the marginal tissue apical to the cemento-enamel junction.<sup>26</sup> Since the soft tissue margin may not be always be composed of gingiva the terms "soft tissue recession" and "marginal tissue recession" is commonly used.<sup>27</sup>

### **ABERRANT FRENUM**

A frenum is a mucous membrane fold containing muscle and connective tissue fibers.<sup>28</sup> It attaches the lip and the cheek to the alveolar mucosa, the gingiva and the underlying periosteum.<sup>29</sup> The frenum may jeopardize gingival health when they are attached too closely to the gingival margin either because of interference with proper placement of the tooth brush or through opening of gingival crevice by muscle pull.<sup>30</sup> Frenum attachments are classified based on its location, as: Mucosal attachment, Gingival attachment, Papillary attachment and Papillary penetrating.<sup>31</sup> Generally the frenum is evaluated in conjunction with vestibular depth. The frenum is of little clinical significance, if there is an adequate zone of attached gingiva coronal to the frenum.<sup>32</sup> However, sometimes maxillary frenum may present with esthetic problems or compromise orthodontic result.<sup>33</sup> Over the years, the relationship between the maxillary midline diastema and the labial frenum has been the subject of much controversy and confusion. Currently, surgical correction is not generally considered until, the eruption of the permanent maxillary anterior teeth is complete.<sup>34</sup>

### **Techniques to correct the aberrant frenum**

Frenotomy is the simple excisional release of the frenum from the apex of its insertion to its base and to the alveolar process. Frenectomy is the complete removal of the frenulum, including its attachments to the underlying alveolar process. Frenotomy and frenectomy can be performed separately as localized procedures or in conjunction with other procedures to increase the zone of attached gingiva.<sup>35</sup>

### **RECONSTRUCTION OF INTERDENTAL PAPILLA**

In health, the interproximal papilla fills the embrasure space to the apical extent of contact area<sup>36</sup>. The position of the gingival tissues around the tooth is determined by the connective tissue attachment level and bone level. The most common reason for loss of interproximal soft tissue in adult individuals is loss of periodontal support due to plaque associated lesions<sup>37</sup>. Orthodontic movement of crowded teeth that are broad and bell shaped invariably results in gingival black holes<sup>38</sup>. Over divergence of adjacent roots during orthodontic therapy can also result in loss of interproximal tissue.<sup>39</sup>

Reconstruction of interdental papilla can be achieved by periodontal procedure (true reconstruction) or restorative procedure (pseudo papillary reconstruction). In true reconstruction free connective grafts are used sandwiched between full thickness flap and alveolar bone or between the connective tissue of partial thickness flap. After the healing period, gingivoplasty may be required to recontour the papilla. Restorative

procedure involves not exactly the manipulation of the papilla but it also involves orthodontic forces or prosthesis placement so as to move the contact point more apically to close the gingival black hole.

## GINGIVAL DE-PIGMENTATION

The color of attached and marginal gingiva is generally described as coral pink and is produced by the vascular supply, the thickness and degree of keratinization of the epithelium and the presence of pigment containing cells (melanocytes).<sup>40</sup> The color varies among different persons and appears to be correlated with the cutaneous pigmentation. It is lighter in blond individuals, with fair complexions than in swarthy, dark haired individuals.<sup>41</sup> The distributions of various pigments in oral mucosa are quite variable, ranging from a focal macule to broad diffuse area. The specific coloration, tint, location, multiplicity, size and configuration of the pigmented lesions are of diagnostic importance.<sup>42</sup>

The mucosal tissues can assume a variety of discoloration. Blue, black and brown discoloration constitute the pigmented lesions of oral mucosa, and such color changes can be attributed to the deposition of either endogenous or exogenous pigments.<sup>43</sup>

The saturation of melanin pigments can cause unaesthetic dark gingival display.<sup>42</sup> This looks even more unaesthetic in people with fair skin and high lip lines. The pigmentation usually occurs in diffuse patches, but sometimes continuous area can be seen.<sup>44</sup>

The choice of treatment is mostly based on the patient's esthetic demands.

### Surgical methods for depigmentation include

- i. Gingivo-abrasion technique: stone/acrylic burs with low speed
- ii. Split thickness epithelial excision: using sharp dissection
- iii. Combination of abrasion a split thickness epithelial excision.

Cryotherapy is a method of tissue destruction by rapid freezing. The cytoplasm of the cell freezes leading to denaturation of proteins and cell death. This procedure does not require the use of local anesthesia, is relatively a painless procedure and has shown to produce excellent results lasting for several years.<sup>45</sup> This procedure does not require even a periodontal dressing. Cryosurgery is easy and safe treatment procedure suitable for both hospital and office based practice. Its major advantage is excellent cosmetic results with minimal scarring.<sup>46</sup>

Various laser techniques for ablation of cutaneous pigmented lesion and oral lesion has been advocated. Among them are, Ruby lasers, Dye lasers, Nd:Yag lasers (Neomymium dimeium yatrium aluminum Garnet laser), Alexandrite, Excimer lasers, Co2 lasers.

Any treatment intended for ablation of melanin should be non-scarring, safe and easy to handle, leave no melanin remnants and carry a low risk of repigmentation.<sup>47</sup>

## ADVANCES IN SURGICAL INSTRUMENTATION: MICROSURGERY

Microsurgery is defined as a "Refinement in existing basic surgical techniques that are made possible by the use of the surgical microscope and subsequent improved visual acuity".<sup>48</sup> Microsurgery has wide implications when applied to all mucogingival surgery procedures, including the free gingival graft for root coverage, because it causes minimal trauma and enhances the wound-healing process.<sup>49</sup> Microsurgery techniques involve minimally invasive procedures utilizing specialized instruments. The combination of small instruments and delicate surgical technique allows for extremely fine and accurate incisions, gentle tissue handling, and precise approximation of wound margins. As a result, rapid wound healing is achieved with low morbidity and less discomfort for the patient. Aesthetic results can also be enhanced with microsurgery through the creation of small surgical wounds and narrow incision lines. Finally, microsurgery provides the operator with improved ergonomics and less fatigue.<sup>50</sup>

## CONCLUSION

Periodontal plastic surgery, evolved from mucogingival surgery. The goal of mucogingival surgery is to produce a functional result, but that of periodontal plastic surgery is to produce both a functional and aesthetic outcome.<sup>51,52</sup> Mucogingival surgeries are the main stream of esthetics in Periodontics. Newer techniques are constantly being developed and are slowly being incorporated into periodontal practice. The practitioner should be aware that, at times, new methods are published without adequate clinical research to ensure the predictability of the results and the extent to which the technique may benefit the patient. Critical analysis of newly presented techniques should guide our constant evolution toward better clinical methods.

## REFERENCES

- 1 David h. Wong, Jerome Cha, 2007. "A periodontal-restorative approach to achieving an esthetic outcome in worn dentition". *Contemporary esthetics*: 11; 24-29.
- 2 Spear FM, Kokich VG, Mathews DP." Interdisciplinary management of anterior dental esthetics." *J Am Dent Assoc*. 2006 Feb; 137(2): 160-69.
- 3 David. A. Garber, Maurice.A.Salama. "The aesthetic smile: diagnosis and treatment". *Periodontology* 2000, Vol. 11, 1996, 18-28.
- 4 Padmanabhan S, Reddy VA. "Inter-disciplinary management of a patient with severely attrited teeth". *J Indian Soc Periodontol* 2010 Jul; 14 (3): 190-94.
- 5 Anita Badersten, Rolf Nilveus, Jan Egelberg. "Effect of nonsurgical periodontal therapy. II Severely advanced periodontitis". *Journal of Clinical Periodontology* Volume 11, Issue 1, January 1984; 63-76.



- 6 Simon Z, Rosenblatt A. "Challenges in achieving gingival harmony". *J Calif Dent Assoc.* 2010 Aug 38 (8): 583-90.
- 7 Tabrizi R, Mirmohamadsadeghi H, Daneshjoo D, Zare S. "Effect of Open Rhinoplasty on the Smile Line". *J Oral Maxillofac Surg.* 2011 Jul 21. [Epub ahead of print].
- 8 Hsu BS. "Comparisons of the five analytic referencelines of the horizontal lip position: their consistency and sensitivity". *Am J Orthod Dentofacial Orthop.* 1993 Oct; 104(4): 355-60.
- 9 Lee RL. "Standardized head position and reference planes for dento-facial aesthetics". *Dent Today* 2000; 19: 82-87.
- 10 Terry DA, McGuire MK, McLaren E, Fulton R, Swift EJ Jr. "Perioesthetic approach to the diagnosis and treatment of carious and noncarious cervical lesions: Part I". *J Esthet Restor.*
- 11 Ritter DE, Gandini LG Jr, Pinto Ados S, Ravelli DB, Locks A. "Analysis of the smile photograph". *World J Orthod* 2006; 7: 279-85.
- 12 Minsk L. "Clinical techniques in Periodontics: Esthetic crown lengthening". *Compend contin Educ Dent* 2001; 22: 562.
- 13 Oh SL. "Biologic width and crown lengthening: case reports and review". *Gen Dent.* 2010 Sep-Oct; 58(5): 200-05.
- 14 Lee EA. "Aesthetic crown lengthening: classification, biologic rationale, and treatment planning considerations". *Pract Proced Aesthet Dent.* 2004 Nov-Dec; 16(10): 769-78.
- 15 Gargiulo AW, Wentz FM, Orban B. "Dimensions and relations of dentogingival junctions in humans". *J Periodontol* 1961; 32: 262.
- 16 Padbury A Jr, Eber R, Wang HL. "Interactions between the gingiva and the margin of restorations". *J Clin Periodontol.* 2003 May; 30(5): 379-85.
- 17 Marangos D. "Treating the gummy smile". *Dent Today* 2011 May; 30(5): 132, 134-36.
- 18 Costa MR, Costa MG, De Pinho CB, Quintão CC. "Correction of severe overbite and gummy smile in patients with bimaxillary protrusion". *J Clin Orthod.* 2010 Apr; 44(4): 237-44.
- 19 Ioi H, Nakata S, Counts AL. "Influence of gingival display on smile aesthetics in Japanese". *Eur J Orthod.* 2010 Dec; 32(6): 633-37.
- 20 Bowers GM. "A study of the width of attached gingiva". *J Periodontol* 1963; 34: 210.
- 21 Ainamo A, Ainamo J. "The width of attached gingiva on supra-erupted teeth". *J Periodontal Res* 1978; 13: 194.
- 22 Miyasato M, Crigger M, Egelberg J "Gingival conditions in areas of minimal and appreciable width of keratinized gingiva, *J Clin Periodontol* 1977; 4: 200.
- 23 Chambrone L, Pannuti CM, Tu YK, Chambrone LA. "Evidence-Based Periodontal Plastic Surgery. II. An Individual Data Meta-Analysis for Evaluating Factors in Achieving Complete Root Coverage". *J Periodontol.* 2011 Aug 22.
- 24 Drofman HS, Kennedy JE, Bird WC "Longitudinal evaluation of free autogenous gingival grafts". *J Clin Periodontol* 1980; 7: 316.
- 25 Niklaus P. Lang, Harald Loe "The relationship between the width of keratinized gingiva and gingival health". *J periodontol* 1972; 43(10): 623-27.
- 26 Khocht A, Simon G, Person P, Denepitiya JL. "Gingival recession in relation to history of hard tooth brush use". *J Periodontol* 1993; 64: 900-05.
- 27 Serino G, Wennstrom JL, Lindhe J, Eneroth L. "The prevalence and distribution of gingival recession in subjects with high standard of oral hygiene". *J Clin Periodontol* 1994; 21: 57-63.
- 28 Fowler EB, Breault LG. "Early creeping attachment after frenectomy: a case report". *Gen Dent.* 2000 Sep-Oct; 48(5): 591-93.
- 29 Peacock ME "Frenotomy and keratinized tissue augmentation". *Gen Dent.* 1998 Mar-Apr; 46(2): 194-96.
- 30 Skurnik H. "Pre-prosthetic considerations — aberrant frena and muscle attachments." *J Can Dent Assoc.* 1973 Aug; 39(8): 534-36.
- 31 Placek M, Skach M, Mrklas L. "Significance of the labial frenum attachment in periodontal disease in man. Part I. Classification and epidemiology of the labial frenum attachment". *J Periodontol* 1974; 45: 891-94.
- 32 Jańczuk Z, Banach J. "Prevalence of narrow zone of attached gingiva and improper attachment of labial frena in youths". *Community Dent Oral Epidemiol.* 1980 Oct; 8(7): 385-86.
- 33 Bagga S, Bhat KM, Bhat GS, Thomas BS. "Esthetic management of the upper labial frenum: a novel frenectomy technique". *Quintessence Int.* 2006; 37(10): 819-23.
- 34 Sorrentino JM, Tarnow DP. "The semilunar coronally repositioned flap combined with a frenectomy to obtain root coverage over the maxillary central incisors". *J Periodontol.* 2009 Jun; 80(6): 1013-17.
- 35 Douglass GL. "Mucogingival repairs in periodontal surgery". *Dent Clin North Am.* 1976 Jan; 20(1): 107-30.
- 36 Cohen B. "Morphological factors in the pathogenesis of periodontal disease". *Br Dent J* 1959; 107: 31.
- 37 Sharma AA, Park JH. "Esthetic considerations in interdental papilla: remediation and regeneration". *J Esthet Restor Dent.* 2010 Feb; 22(1): 18-28.
- 38 LaVacca MI, Tarnow DP, Cisneros GJ. "Interdental papilla length and the perception of aesthetics". *Pract Proced Aesthet Dent.* 2005 Jul; 17(6): 405-12.
- 39 Inocencio F, Sandhu HS "Interdental papilla reconstruction combining periodontal and orthodontic therapy in adult periodontal patients: a case report". *Can Dent Assoc.* 2008 Jul-Aug; 74(6): 531-35.
- 40 Mehta P, Lim LP "The width of the attached gingiva – much ado about nothing?" *J Dent.* 2010 Jul; 38(7): 517-25.
- 41 Dummett CO "Physiologic pigmentation of the oral and cutaneous tissues in the negro". *J Dent Res* 1946; 25: 421.
- 42 Nilima S, Vandana KL "Melanin: a scavenger in gingival inflammation". *Indian J Dent Res.* 2011 Jan-Feb; 22(1): 38-43.
- 43 Brooks JK, Nikitakis NG. "Emergent gingival pigmentation. Oral melanotic macule". *Gen Dent.* 2010 May-Jun; 58(3): 266-68.
- 44 Dummett CO "Oral pigmentation: physiologic and pathologic". *NY State Dent J* 1959; 25: 407.
- 45 Halm Tal, Jacob Landsberg, Avital Kozlovsky "Cryosurgical depigmentation of the gingiva - A case report". *J Clin Periodontol* 1987; 14(10): 614-17.
- 46 Arikan F, Gürkan A. "Cryosurgical treatment of gingival melanin pigmentation with tetrafluoroethane". *Oral Surg, Oral Med, Oral Pathol, Oral Radiol, and Endodontol* 2007; 103 (4): 452-57.
- 47 Stabholz A, Zeltser R, Sela M, Peretz B, Moshonov J, Ziskind D, Stabholz A. "The use of lasers in dentistry: principles of operation and clinical applications". 2003; *Compend Contin Educ Dent.* 24 (12): 935-48.
- 48 Shanelec DA. "Periodontal microsurgery". *J Esthet Restor Dent.* 2003; 15(7): 402-07.
- 49 Tibbetts LS, Shanelec DA. "Review of the principles and practice of periodontal microsurgery". 2007 *Tex Dent J*; 124(2): 188-204.
- 50 Hegde R, Sumanth S, Padhye A. "Microscope-enhanced periodontal therapy: a review and report of four cases". *J Contemp Dent Pract.* 2009; 10(5): 88-96.
- 51 Miller PD Jr "Root coverage using a free soft tissue autograft following citric acid application. Part 1 technique, *Int J Periodont Restor Dent* 1982; 2: 65.
- 52 Friedman N, Levine HL "Mucogingival surgery: Current status", *J Periodontol* 1964; 35: 5.