

BIFID MANDIBULAR CONDYLE: A VERY RARE ENTITY

¹SMITA KAMTANE, BDS, MDS

²ARUN SUBRAMANIAM, BDS, MDS

ABSTRACT

Bifid Mandibular Condyle is described in the literature as a very rare entity, usually diagnosed on routine radiographic examination. The etiopathogenesis of Bifid Mandibular Condyle still remains controversial and proper description of the condition is not defined owing to fewer reported cases. Herein, a case of unilateral bifid condyle in Indian population is reported.

Key words: Unilateral, Condyle, Bifid, very rare entity

INTRODUCTION

Bifid mandibular condyle is considered a rather uncommon condition, diagnosed radiographically. It is characterized by the duplicity of the head of the mandibular condyle; thus it is also known as double-headed condyle and it may be associated with a variety of symptoms. Two articulating surfaces of the bifid condyle are divided by a groove and can be oriented mediolaterally or anteroposteriorly. The anomaly may occur on both sides but is frequently unilateral, apparently without any marked predilection for any one side.

The condition was not cited in the main treatise of skull morphological variants. It was first described by Hrdlica¹ in 1941 who found 21 cases in the Smithsonian Institution's collection of dried skulls. It is, until now, the most richly illustrated descriptions of this anomaly. After him, Szentpetery² found seven bifid mandibular condyles on 1882 prehistoric and historic skulls with 2007 condyles from the collection of Hungarian skulls (Neolithic-18th).

The first report of this condition in a living population was made in 1948 by Schier.³ A second and well documented report of this abnormality was given by Standnicki⁴ in 1974. At the moment, only 40 cases have been reported in literature.⁵ Although the number of reports continues to accumulate, the bifid mandibular condyle remains a relatively uncommon entity. This is due to the minimal symptomatology. It is usually

discovered as an incidental finding on panoramic radiographs. Therefore, in human remains and living population these findings are exceptional. The purpose of this article is to report a unique case of unilateral bifid condyle and to review the relevant literature. To the best of our knowledge this is fifth case of unilateral bifid condyle to be reported in the Indian population.

CASE REPORT

A 16 year old female patient came to the Department of Oral Medicine & Radiology with the chief complaint of limited mouth opening and cosmetic disfigurement. Limited mouth opening was present since birth. Patient had difficulty in swallowing and speech. No history of trauma was revealed. Also, no history of snoring or drug intake was given.

Clinical examination of the head and neck region revealed a marked mandibular micrognathia (Figure 1), resulting in a typical "bird face" appearance with incompetent lips. This skeletal relationship was Angle's Class II Division 1 with traumatic occlusion. There was crowding in the lower dental arch with palatally 12 (Figure 2). Interincisal opening was restricted to 30 mm (between incisal edges of the central incisors) and the condyles could only perform rotatory movements. Both protrusive and lateral excursions were limited.

The panoramic radiograph revealed a short condyle on the right side, the heads of which manifested signs

¹Department of Oral Medicine & Radiology, Dr DY Patil Dental College & Hospital, PUNE, India

²Department of Oral Medicine & Radiology

Correspondence to: Dr Smita Kamtane, Girnar House, Flat No. 102, Adarsh Society, Market Yard Road, Pune-411037, Maharashtra, India Ph: 09226246328, (020) 24265399, Email: smita_kamtane@yahoo.com

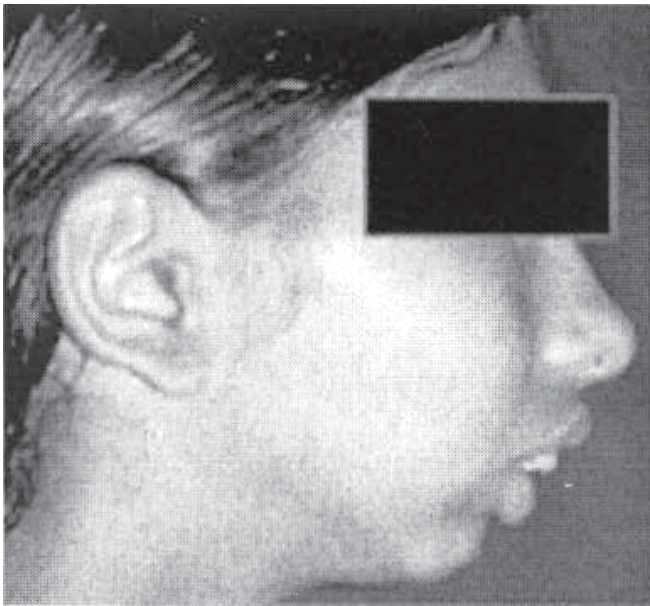

Fig 1: Extraoral examination of the patient showing mandibular micrognathia

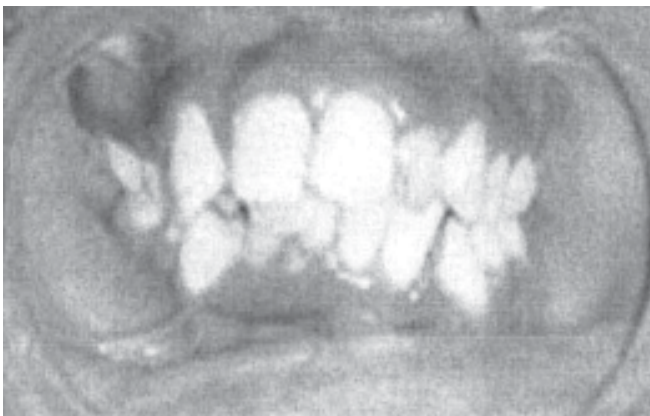

Fig 2: Intraoral examination showing crowding in the lower dental arch

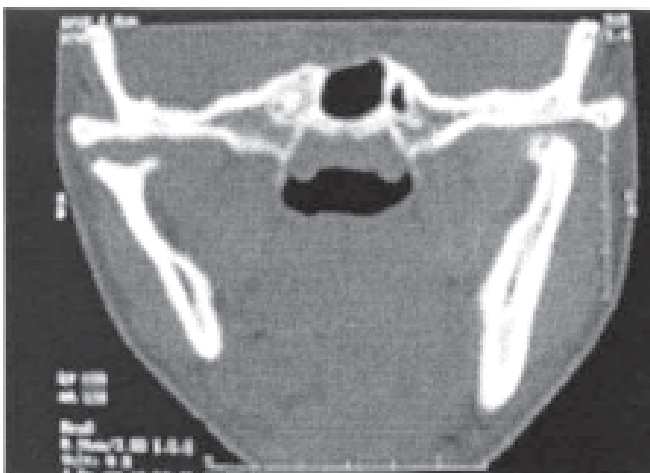


Fig 3: CT scan of mandible showing bifid right condyle

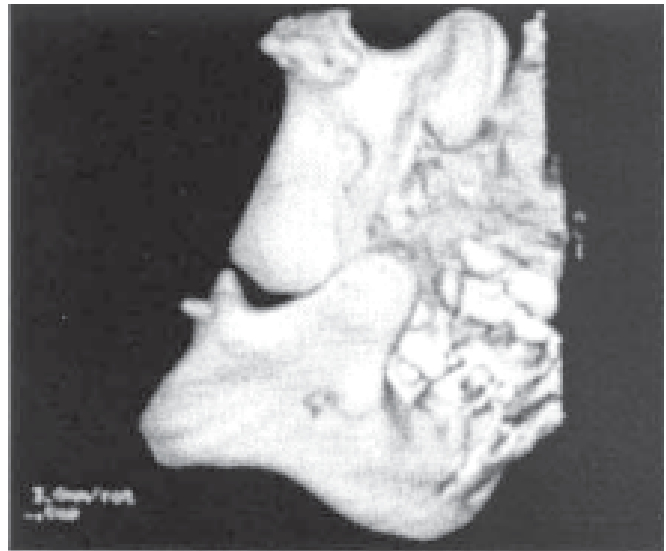


Fig 4: Three dimensional CT scan of mandible showing bifid right condyle

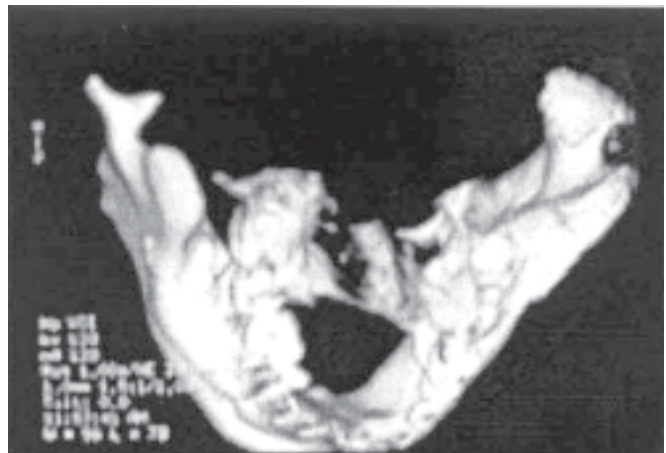

Fig 5: Three dimensional CT scan of mandible showing Y shaped appearance of right condyle

of duplication. Further investigation with axial and coronal spiral computed tomography (CT) confirmed the markedly deformed appearance of the right condyle and the significant asymmetry of the temporal fossae. The right condyle had a "Y-appearance", with 2 distinct medial and lateral heads. The medial head had a thin sclerotic margin and was within the glenoid fossa (Figs 3, 4, 5).

Based on the clinical and radiographic findings, a diagnosis of unilateral bifid condyle on the right side was made. A combined orthodontic-surgical treatment was recommended for the correction of the facial skeletal anomaly, mouth opening and the mandibular movements during function.

DISCUSSION

According to the literature, the bifid condyle is a rare entity, as only 40 cases in living patients have been reported. Concerning the unilateral bifid condyle, it is found that there is no age predilection. The age of the patients range from 3 to 67 years (mean age, 35 years) and the male/female ratio is approximately 1.5:1. Bifid condyles appear to involve the left side more than the right side (15 of 25 cases with available data).⁶

Bifid condyle is a very rare entity. Two main causes of bifid condyle have been suggested²; traumatic or developmental. In living subjects, reports of bifid condyle fall within one of these two groups: those with a history of trauma and those without. The most tenable theory of its origin is that it is of traumatic origin.⁷ Minor trauma to the condyle "growth center" may result in condylar bifidism, which would then represent a developmental anomaly. Otherwise, the insufficient remodeling of the condylar bony fragment might give rise to the bifid condylar formation. According to the current English literature, history of condylar trauma is evident in approximately 25% of all cases reported.⁸ In this case no history of trauma was revealed.

Symptoms described with bifid condyles vary from case to case, but in most instances symptoms are absent. The most common and predominant symptoms are TMJ sounds, pain, restriction of mandibular movement, trismus, swelling, ankylosis, and facial asymmetries are also described.⁷ In this case, snoring and the mandibular hypoplasia were the patient's chief complaints, which motivated her to seek medical assistance.

The diagnosis of the bifid condyle is based on its radiographic appearance, which is almost always found

by chance. The bifid condyle may be discovered on dental radiographic examination or during the investigation of another problem.⁹ The ideal method for the detailed evaluation of condylar morphology seems to be coronal computed tomography.¹⁰

The treatment of the symptomatic bifid condyle is usually conservative and similar to the treatment for the closely associated TMJ pain dysfunction syndrome, namely analgesics and anti-inflammatory agents, muscle relaxants, physiotherapy, splint.

REFERENCES

- 1 Hrdlicka A. Lower jaw: double condyles. *Am J Phys Anthropol* 1941; 28: 75-89.
- 2 Szentpetery A., Kocsis G, Marcsik A. The problem of the bifid mandibular condyle. *J Oral Maxillofac Surg* 1990; 48: 1254-57.
- 3 Schier MBA. The temporo mandibular joint: a consideration of its probable functional and dysfunctional sequelae and report: condyle-double in a young person. *Dent Items Interest* 1948; 70: 1095-1109.
- 4 Stadnicki G. Congenital double condyle of the mandibular joint ankylosis: report of case. *J Oral Surg* 1971; 29: 208-11.
- 5 Garcia-Gonzalez D, Martin-Granizo R, Lopez P. Imaging quiz case 4. *Arch Otolaryngol Head Neck Surg* 2000; 126(6): 795.
- 6 Antoniadis K, Karakasis D, Eleftheriades J. Bifid mandibular condyle resulting from a sagittal fracture of the condylar head. *Br J Oral Maxillofac Surg* 1993; 31: 24-26.
- 7 Quayle AA, Adams JE. Supplemental mandibular condyle. *Br J Oral Maxillofac Surg* 1986; 24: 349-56.
- 8 To EW. Mandibular ankylosis associated with a bifid condyle. *J Craniomaxillofac Surg* 1989; 17: 326-28.
- 9 Shaber EP. Bilateral bifid mandibular condyles. *J Craniomandibular Practice* 1987; 5: 191-95.
- 10 Kahl B, Fischbach R, Gerlach KL. Temporomandibular joint morphology in children after treatment of condylar fractures with functional appliance therapy: a follow-up study using computed tomography. *Dentomaxillofac Radiol* 1995; 24: 37-45.