

## TREATMENT OUTCOME OF SURGICAL MANAGEMENT IN ENDODONTIC RETREATMENT FAILURE

<sup>1</sup>SHIRAZ PASHA, BDS, MDS

<sup>2</sup>MADHU K S, BDS, MDS

<sup>3</sup>SHRUTHI NAGARAJA, BDS, MDS

### ABSTRACT

*Preservation of a patient's natural dentition remains an important outcome in securing oral health. Dentists and patients are facing a perplexity between saving a compromised tooth through endodontic treatment, retreatment or extraction. Though success rates of endodontic initial treatment have been improving over the years, persistence of periapical disease is far from being a rare condition. The most common therapeutical options for the re-treatment of teeth with periapical pathosis are non-surgical orthograde treatment and surgical treatment. Selection between alternative treatments should be based on assessment of respective benefits mainly healing. This paper reports two cases treated surgically due to failure of ortho-grade treatment and healed completely when followed-up over a period of 1 year. The method of evaluation of the healing was through radiographic method and clinical method.*

**Key Words:** Endodontic surgery, Periapical Lesions, Ortho-Grade Root Canal Treatment.

### INTRODUCTION

The main objective of root canal treatment is thorough mechanical and chemical debridement of the entire pulp space, three dimensional obturation of radicular space and a permanent coronal filling to promote healing of existing pathology and prevent the development of any new infection.<sup>1,2</sup> The cause of the endodontic failure is often multivariant. Causes of failure include incomplete obturation, root perforation, external root resorption, coexistent periodontal-periradicular lesions, grossly overfilled or overextended canals, canals left unfilled, developing apical cysts, adjacent pulpless teeth, inadvertently removed silver points, broken instruments, unfilled accessory canals,

constant trauma, and nasal floor perforation.<sup>3</sup> In cases of endodontic treatment failure, the infection continues to persist in the intricate areas of the canal which in turn is responsible for re-infection in the peri apical area. In such situations endodontic surgery is the treatment modality of choice.

Endodontic surgery once thought to be the treatment of last resort, has advanced in the recent years to increase the clinicians ability to achieve more predictable clinical outcome.<sup>3</sup> Despite the recent advances, endodontic surgery is not new to contemporary dentistry. The first recorded endodontic surgical procedure was the incision and drainage of an acute endodontic abscess.<sup>4</sup> The investigations and techniques developed in the middle of twentieth century has laid the foundation for the current concept of surgical intervention.<sup>4</sup> Conventional orthograde treatment remains the preferred treatment of choice before considering retro-grade attempt for treating pulpal diseases in cases which do not respond to the conventional root canal treatment.<sup>5</sup> In situations of failed Ortho-Grade treatment due to persistent symptoms and lesion, the reason of failure should be ascertained further by the clinician to establish the line of treatment.<sup>5</sup> Periradicular curettage is a procedure to remove any soft-tissue lesion from around the root apex with the idea of eliminating the focal of infection.<sup>6</sup> It may not be possible to remove all the soft tissue until the root end is resected.<sup>6</sup>

<sup>1</sup> Assistant Professor, Department of Conservative Dentistry and Endodontics, Rajiv Gandhi Dental College & Hospital, Hebbal Bangalore – 560032 Karnataka, India Mob: 9845575074, Email: shiraz\_pasha@yahoo.co.in

<sup>2</sup> **Corresponding author:** Asst Professor, Department of Conservative Dentistry and Endodontics M.S. Ramaiah Dental College & Hospital, M.S.R. Nagara, M.S.R.I.T. Post, Bangalore – 560054 Karnataka, India Mob: 9740126193, Email: madhusrinivas5@yahoo.co.in

<sup>3</sup> Assistant Professor Department of Conservative Dentistry and Endodontics M.S. Ramaiah Dental College & Hospital M.S.R. Nagara, M.S.R.I.T Post, Bangalore – 560054 Karnataka, India Tel: 080-26597547, Mob: 9886464095 Email: nagaraja.shruthi@gmail.com

**Received for Publication:** September 11, 2013

**Revision Received** September 28, 2013

**Accepted:** October 18, 2013

The following two case reports highlights the need of surgical treatment in a non healing lesions, remarkable healing in the follow up which were evaluated based on Rudd's Criterion.<sup>7</sup>

## CASE SERIES

### *Case Series 1*

A female patient aged 23 years reported to the Department of Conservative Dentistry and Endodontics of Rajiv Gandhi Dental College and Hospital, Bangalore with the chief complain of swelling and pain in the lower front teeth. On detailed case history recording, the patient revealed that she had undergone root canal treatment of the lower tooth one year back and was asymptomatic initially followed by occasional pain and swelling intermittently. The continuous throbbing pain started 10 days before the visit, accompanied with swelling in the same region since one week. The medical history of the patient was non-contributory.

On intra-oral examination, diffuse swelling was present irt 41, 31 which was soft and tender to palpation with obliteration of the vestibule and cortical plate. Tenderness to vertical percussion was seen irt 41, 42, 31 and 32. The mobility and probing depths were within normal physiological range. No response was elicited irt 31, 32, 41, 42 on vitality testing. On radiographic examination, intra-oral periapical radiograph revealed unsatisfactory obturation irt 31 and diffuse radiolucency involving periapical area of 31 and 41, extending to 32 and 42 (Fig 1a). Diagnosis of Acute Exacerbation of Chronic Apical lesion due to failed root canal treatment wrt 31 was made.

Root canal treatment was initiated for 31, 32, 41, and 42. Access cavity was prepared using endodontic access bur FG no 1 (Dentsply Maillefer, Switzerland). The gutta percha was removed from the previously filled canal. At this stage, a missed lingual canal was detected irt 31 clinically. Working length was determined radiographically and confirmed with an apex locator (Ray Pex 5, Dentsply Maillefer, Switzerland). Chemomechanical Preparation was done upto apical size 50 (Densply Maillefer, Switzerland) using Pressureless Crown down Technique alternated with 2.25% sodium hypochlorite (Multilabs, India) diluted with saline. Calcium hydroxide (Prime Dental, India) aqueous suspension was placed inside the root canals as a medicament. One week after the first visit the patient presented without any symptoms. Master cones # 50 (Dentsply Maillefer, Switzerland) were selected

and obturation was done by cold lateral condensation technique using gutta-percha and AH Plus sealer (Dentsply Maillefer, Switzerland). Permanent access filling was done using Composite filling material (Z 250 Universal restoration, 3M ESPE, Filtek, US).

The patient was recalled after three months and clinical examination showed all treated teeth were symptomatic and radiograph revealed no changes in the periapical radiolucency. As Endodontic surgery was the next treatment option and patient consent was obtained. Routine blood investigations showed normal physiological results.

Patient was prepared for surgery. After giving local anesthesia using 2% lidocaine with 1: 1000,000 epinephrine (Lox 2%, India) a mucoperiosteal flap was elevated by Luebke Ochsenbein method and curettage was done to remove the granulation tissue. Apicoectomy (Stryker 2296 carbide bur, US) of 3mm was performed (Fig 1b). The flap was repositioned back in place and interrupted sutures (Hu-Friedy, US) were placed. Coepak (GC, Japan) was placed. The soft tissue removed from the periapex was sent for histological evaluation. The histopathological evaluation revealed the presence of chronic infected granulation tissue. The patient was periodically assessed for healing. The recall visit after 1 year showed complete healing according to Rud' criteria<sup>7</sup> with no clinical symptoms (Fig 1c).

### *Case Series 2*

A male patient aged 32 years reported to the Department of Conservative Dentistry and Endodontics of Rajiv Gandhi Dental College and Hospital, Bangalore with the chief complaint of swelling and pain in lower front teeth since 3 weeks. Clinical examination revealed tenderness on vertical percussion wrt 41, 31 and 32 and no response to vitality test irt 32. Radiographic examination revealed presence of a radio-opaque filling suggestive of silver point obturation irt 31 and 32 with a diffused periapical radiolucency in the same region (Fig 2a). Diagnosis of acute apical abscess was arrived at, based on the clinical and radiographic examination.

Root canal treatment was initiated for 31, 32 and 41. Access cavity was prepared using endodontic access bur FG no 1 (Dentsply Maillefer, Switzerland) the silver points were retrieved using braided technique with H-files (Dentsply Maillifer, Switzerland). Endodontic retreatment was done similar to previously mentioned Case report 1 and obturated using gutta-percha and AH plus sealer (Dentsply Maillefer, Switzerland). Due

to persistent symptoms and non healing lesion, patient was posted for surgery after 3 months. After routine pre surgical investigations, mucoperiosteal flap was elevated by Luebke Ochsenbein method under local anesthesia (2% lidocaine with 1: 1000,000 epinephrine). Periapical curettage was done to remove the granulation tissue and surgical debridement was also done as described in the previous case and immediate radiograph was taken (Fig 2b). Periodic follow up showed subsiding symptoms and healing lesion. The patient was asymptomatic clinically and showed healing radiographically over a period of 1year (Fig 2c). The healing response was evaluated based on Rudd's Criterion.<sup>7</sup>

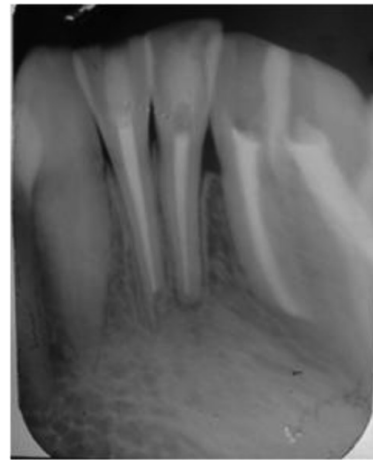


Fig 1c: 1year Post-operative Radiograph showing complete bone healing.

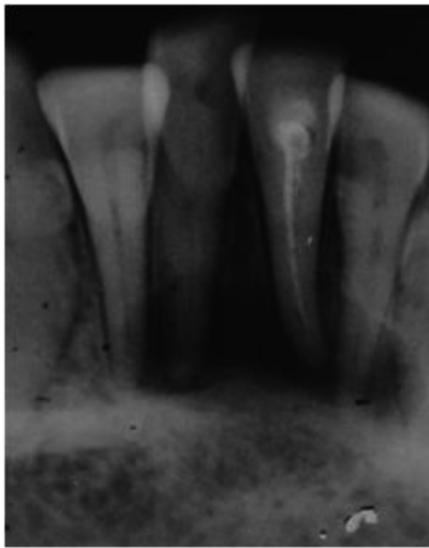


Fig 1a: Pre-operative Radiograph wrt 31, 32, 41, 42 showing large periapical lesion and poor obturation wrt 31

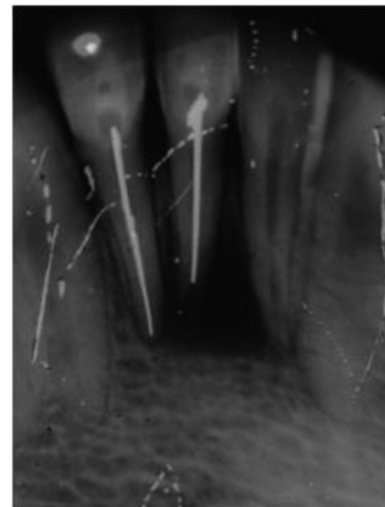


Fig 2a: Pre-operative Radiograph wrt 31,32,41 showing large periapical lesion and silver point obturation wrt 31, 32.

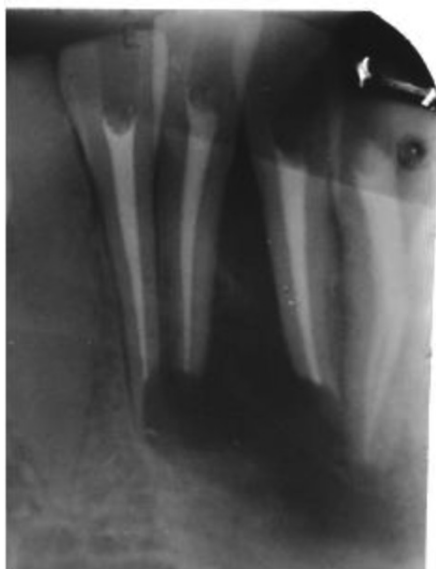

Fig 1b: Immediate Post-operative radiograph showing apicectomy done wrt 32,31,41,42.

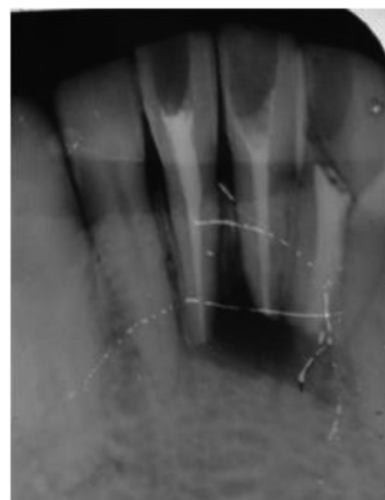


Fig 2b: Immediate post-surgical radiograph wrt 32, 31, 41.

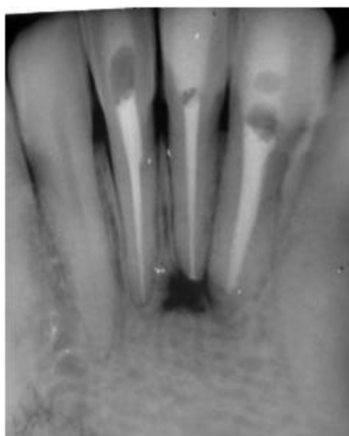


Fig 2c: one year post-operative Radiograph.

## DISCUSSION

Periradicular surgery is an alternative definitive procedure in failed conventional endodontic treatment. In addition to the elimination of pathology and enhancing healing, it also ensures prevention of new lesion by retrograde treatment. Periradicular surgery usually comprises curettage, resection of the apical root third (apicoectomy), preparation of root-end cavity, and placement of a retrofilling material, removal of any separated instrument etc based on the condition.<sup>8</sup>

Studies have reported the incidence of two canals i.e second lingual canal is 36.25% in mandibular central and lateral incisors.<sup>9</sup> 42% incidences of missed roots or canals were discovered as one of the reason for endodontic treatment failure.<sup>3</sup> The location of the second lingual canal can be done by studying the pre-operative radiograph carefully, extending the access cavity lingually and pre-enlarging with gates glidden drills.

In case 1, one of the reason for failure of endodontic treatment may be missed lingual canal in the lower central. With the knowledge of internal anatomy of mandibular anterior teeth and careful visualization, the second lingual canal was located and obturated.

In case 2, failure in the endodontic treatment may be due to inadequate seal by silver point obturation. Silver points were most commonly used in previous times which were not designed efficiently and were of lesser quality metallurgy, which prevented accurate preparation of the canal space. Silver points are machined round and obturated in oval canals that will eventually lead to micro-leakage around the silver points. Silver points are also prone to corrosion when exposed to the moist environment which is known to corrode over a period of time.<sup>10</sup>

In both the cases the periapical lesions were followed up for 3 months after non-surgical orthograde re-treatment and due to persistent symptoms, endodontic surgery was planned and carried out. Signs of healing were seen at 3 month follow up after the surgery and complete healing at 1 year follow up radiographs

according to Rudd's criteria for healing after periapical surgery around the resected roots in both the cases.<sup>6</sup> Even though endodontic surgery remains predictable treatment of choice for repeatedly failing endodontic treatment, an orthograde retreatment for favorable results should be attempted.

## SUMMARY

Failure of conventional orthograde treatment may be due to failure to remove the infection completely or due to re-infection. Orthograde retreatment should be the treatment choice for failed cases. In spite of this, there may be persisting clinical symptoms or non-healing lesions, that dictates the need for more definitive and advanced treatment i.e periradicular surgery. In the two case reports, failed previous root canal treatments due to missed canal and silver point obturation in the mandibular lower anteriors with large periapical lesion were reported. Orthograde retreatment performed failed to show any reduced symptoms or signs of healing. Endodontic surgery—Apicoectomy and Periapical curettage was done accordingly where indicated. The follow-up visits showed no clinical symptoms eventually and complete satisfactory healing of the periapical lesion. This report highlights the need for extensive treatment option in failed conventional endodontic treatment for predictable results.

## Conflict of interest

Authors declare that there was no conflict of interest in publishing these case reports.

## REFERENCES

- 1 Barker BCW, Parson KC, Mills PR, Williams GL. Anatomy of root canals. III. Permanent mandibular molars. *Aust Dent J* 1974; 19: 403-13.
- 2 Vertucci FJ. Root canal anatomy of the human permanent teeth. *Oral Surg Oral Med Oral Path* 1984; 58: 589-99.
- 3 Hoehn MM, Pink FE. Contemporary Endodontic Retirements: An Analysis based on Clinical Treatment Findings. *J Endod*. 2002 Dec; 28(12): 834-36.
- 4 Guerini V. A history of dentistry. Philadelphia, Lea and Febiger; 1909. p. 117.
- 5 Kim S. Principles of endodontic surgery. *Dent Clin North Am* 1997; 41: 481-97.
- 6 Peters L, Wesselink P. Soft tissue management in endodontic surgery. *Dent Clin North Am* 1997; 41: 513-28.
- 7 Rud J, Andreasen JO, Jensen JE. Radiographic criteria for the assessment of healing after endodontic surgery. *Int J oral surg* 1972; 1: 195-14.
- 8 John Ide Ingle, Leif K. Bakland, J. Craig Baumgartner Ingle 6<sup>th</sup> Edn Ingle's Endodontics 6. p. 1233.
- 9 Boruah LC, Bhuyan AC. Morphologic characteristics of root canal of mandibular incisors in North-East Indian population: An in vitro study. *J Conserv Dent*. 2011; 14(4): 346-50.
- 10 Soares JA, Nunes E, Silveira FF, Santos SMC and Oliveira MTF. Endodontic re-treatment associated with the elimination of amalgam root-end filling through sinus tracts: A report of two cases. *Aust Endod J* 2009; 35: 59-64.