

SOFT TISSUE CHANGES WITH RETRACTION IN BI-MAXILLARY PROTRUSION ORTHODONTIC CASES

¹RASHNA H SUKHIA, BDS, FCPS (Orth), M Orth RCS (Ed)

²HR SUKHIA, BDS, BSC MS (Orth) MFDSRCS (UK) M Orth RCS (Ed)

³SAROSH MAHDI, BDS, MPH (UK)

ABSTRACT

To investigate the profile soft tissue changes, and associated dental and skeletal effects, in upper and lower incisors following 1st premolar extraction and incisor retraction in bimaxillary proclination orthodontic cases.

Thirty-five patients (M:F ratio 18:17) with bimaxillary protrusion with age ranging from 14-17 years (mean calculated age 15.6 years) were treated with 1st premolar extractions followed by retraction of the upper and lower labial segments with fixed orthodontic appliances.

Pre and post cephalometric values were recorded for each patient. The angular and linear soft tissue parameters measured were the naso-labial angle, labio-mental angle and the upper and lower lips distance to Ricketts esthetic plane to investigate the soft tissue changes compared with incisor retraction following treatment. The skeletal parameters measured were SNA, SNB, ANB, MMA, SN-MP and the facial height ratio, while the dental parameters measured were upper incisors to maxillary & SN plane, lower incisors to mandibular plane and the inter-incisal angle. Pre and post cephalometric values were calculated separately for each patient and the mean value was calculated.

The upper lip prominence decreased by 3mm while the lower lip retracted by 5 mm following 1st premolar extraction space closure and retraction of the upper and lower labial segments. The naso-labial angle showed 4 degrees mean value change following upper incisor retraction, while the labio-mental angle demonstrated a mean value change of 2 degrees post-treatment.

The facial soft tissue profile demonstrated both angular and linear changes post-treatment following 1st premolar extractions and incisor retraction in bi-maxillary proclination patients, followed by dental changes while skeletally the lower facial height dimension reduced post-treatment.

Key Words: *Bi-maxillary proclination, Orthodontic treatment, Lower Facial Height, Premolar extraction, soft tissue profile.*

INTRODUCTION

In orthodontics, bi-maxillary proclination is defined as the concomitant proclination of the upper and lower dental arches.¹ It is most common in afro-caribbeans and oriental populations. Skeletal bi-maxillary protrusion

or prognathic jaws is usually associated with prominent everted lips, convex facial profile, accentuated ANB angle, short posterior cranial base, anterior positioned glenoid fossa and divergent facial planes.²

Soft tissue profile changes following premolar extractions is a well researched topic in orthodontics.³⁻⁴ Most orthodontists⁵⁻⁶ agree that upper and lower 1st premolar extractions are required to flatten the profile, to reduce any overjet, to enable lip competence and to improve facial esthetics. Most bimaxillary protrusion adult cases complain of increased facial height and lip protrusion rather than the dental protrusion. This is due to the increased esthetic awareness in recent years amongst the adult population.⁷

Corresponding Author & Address:

¹ Prof. Dr. HR Sukhia, Vice-Principal & Head of Dental Section, Street 32, Block 5, Boat Basin, Clifton, Sir Syed College of Medical Sciences, Karachi.

² Assistant Professor of Orthodontics & Head of Department, Sir Syed College of Medical Sciences, Karachi

³ Assistant Professor of Community Dentistry & Head of Department Jinnah Medical & Dental College, Karachi
E-mail: hsukhia@hotmail.com

Received for Publication: August 14, 2013

Accepted: September 14, 2013

Some authors⁸⁻⁹ have a strong negative view of extraction treatment, which they believe produces a dished-in profile, flattens the face and reduces the lower facial height giving the patient an older aged appearance. Other orthodontists¹⁰⁻¹¹ reject this flattening of the face theory and have reported a more esthetically pleasing profile and anterior-posterior improvement in facial profile after four 1st premolar extractions.

Most recent studies¹²⁻¹³ have investigated changes in soft tissue profile with four 1st premolar extractions, however, few researchers have focused on both angular and linear profile changes both antero-posteriorly and vertically in bi-maxillary cases. Therefore, our present study aims to address the pre- and post treatment soft tissue profile changes, and associated dental and skeletal effects, in bi-maxillary proclination cases after 1st premolar extractions concentrating particularly on the lower anterior region, which is prone to the greatest changes by treatment.

METHODOLOGY

In the study, 35 patients (male: female ratio 18:17) with class 2 skeletal malocclusions and bi-maxillary dental proclination were selected and treated with fixed orthodontic appliances. All the patients were between 14 and 17 years age at the beginning of treatment (mean calculated age 15.6 years). The mean values of crowding were 7.2 mm in upper arch and 6.4 mm in the lower arch.

All the patients were treated with Roth 0.022" prescription straight-wire fixed appliances. The total treatment was between 14 to 24 months. The treatment objectives were to ideally align the incisors, correct the incisor inclinations, close the pre-molar extraction spaces and provide an esthetically pleasing profile.

Inclusion Criteria

- Patients having bimaxillary dental protrusion i.e. Proclined upper and lower labial segments and procumbent protrusive lips.
- Increased vertical dimensions or long-face patients.
- Patients requiring 1st 4 premolars extractions for orthodontic treatment.

Exclusion Criteria

- No functional appliance or orthognathic surgical procedure between pre- and post- treatment lateral cephalometric radiographs.
- No congenitally missing teeth (excluding 3rd molars).

The dental, skeletal and soft tissue measurements were investigated using pre- and post treatment lateral cephalometric tracings exposed at the beginning and end of treatment. All radiographs were taken in standing position, with the frankfort horizontal plane parallel to the floor, the dentition in centric occlusion and the lips relaxed.

Standardized cephalometric radiographs measuring 8" X 10" were taken using a Siemens Orthophos-C cephalostat with settings of 14m A, and between 73 and 77 kV. Exposure time varied between 0.5 and 0.63 seconds. The film used was either Kodak TMG-RA1 or DuPont Ultravision G, with a developing time of 90 seconds using a Kodak N35 developer.

Statistical Method

SPSS program 10.0 (Statistical Package for Social Sciences) was used for statistical evaluation. Mean and standard deviation was calculated. As noted in our study, dental cephalometric values were not included in the results. Only the skeletal and soft tissue parameters were investigated.

Skeletal Parameters Measured

The Skeletal angular parameters measured with pre- and post- treatment lateral cephalogram tracings were done to verify the skeletal contribution to the bi-maxillary protrusion cases (Fig 1).

SNA: Sella-Nasion line with maxillary apical base point A. (Normal value $82^{\circ} \pm 2^{\circ}$)

SNB: Sella-Nasion line with the mandibular apical base point B. (Normal value $80^{\circ} \pm 2^{\circ}$)

ANB: Difference between SNA & SNB. (Normal value $2^{\circ} \pm 2^{\circ}$)

MMA: Maxillary plane to mandibular plane angle. (Normal value $26^{\circ} \pm 5^{\circ}$)

SN-MP: Sella-Nasion to mandibular plane angle. (Normal value $32^{\circ} \pm 5^{\circ}$)

Facial Height Ratio: Mentum to anterior nasal spine (ANS) to Nasion-Mentum distance measured in millimeters (Normal value range 50-55%)

Dental Angular Parameters Measured (Fig 1):

I/MP: Upper incisor to maxillary plane angle. (Normal value $108^{\circ} \pm 6^{\circ}$)

U/SN: Upper incisor to Sella-Nasion plane. (Normal value $103^\circ \pm 6^\circ$)

IMPA: Lower incisor to mandibular plane angle. (Normal value $93^\circ \pm 6^\circ$)

Inter-Inc Angle: The angle between the long-axis of the most prominent upper and lower incisors (Normal value $133^\circ \pm 10^\circ$)

Soft Tissue Angular Parameters Measured:

Naso-labial Angle: It is defined as the angle between the line tangent from the sub-nasale (Sn) to the lower border of the nose, and from Sn to the vermilion border of upper lip (Fig 2).

Labio-mental Angle: It is formed by the intersection of the line drawn between the sulcus inferior an soft tissue chin and a line originating at sulcus inferior tangent to lower lip. Most investigations¹⁴⁻¹⁵ have determined that at mean 18 years age, the normal value is $125^\circ \pm 12^\circ$ in males and $127^\circ \pm 12^\circ$ in females. In our present study we have taken the mean of $130^\circ \pm 5^\circ$ as normal (Fig 2).

Esthetic Plane: The esthetic plane joins the tip of

the nose (Pr) with the soft tissue pogonion (Pg') (Fig 3). The upper & lower lip vermilion border to E-Plane distance is measured in millimeters perpendicularly. The normal value for the upper lip is $-4\text{mm} \pm 2\text{mm}$, while the lower lip normal value is $-2\text{mm} \pm 2\text{mm}$. Negative sign denotes lips are behind or retruded to the esthetic plane.

RESULTS

The mean pre-and post-treatment values of the patients in our study are shown in Table 1.

Pre- & Post-Treatment Skeletal Measurements:

The skeletal cephalometric parameters measured before and after treatment showed significant vertical and anterior posterior changes. The pre-treatment SNA, SNB mean values showed that the patients selected for the study had an underlying skeletal class 2 base with an increased mean ANB value of 7° . The major contribution to skeletal class two malocclusion was due to a prognathic maxilla as evident from the pre-treatment mean SNA value of 87° . The pre-treatment SNB value of 82° also confirms the presence of a slight associated

TABLE 1: MEAN VALUES OF PRE- AND POST TREATMENT CEPHALOMETRICS

No.	Parameter measured	Normal value	SD \pm	Pre-treatment Mean	Post-treatment mean	Mean difference
a. Skeletal AP and vertical measurements						
1	SNA<	82°	2°	87°	85°	2°
2	SNB<	80°	2°	82°	81°	1°
3	ANB<	2°	2°	7°	4°	3°
4	Max-Man.plane<	26°	5°	33°	30°	3°
5	SN/ Man.plane <	32°	5°	37°	33°	4^{***}
6	Facial Height Ratio	50-55%		56%	53%	3^{***}
b. Dental measurements						
7	UInc/Max plane <	108°	6°	117°	110°	7°
8	UInc/ SN plane <	103°	6°	111°	105°	6°
9	IMPA	93°	6°	106°	97°	9^{***}
10	Inter-Inc <	133°	10°	124°	137°	13^{***}
c. Angular Soft tissue measurements						
11	Naso-labial <	100°	5°	86.2°	90.4°	4^{***}
12	Labio-mental <	130°	5°	124.3°	126.2°	2°
d. Linear Soft tissue measurements						
13	U.lip/E-plane	-4mm	2 mm	+2mm	-1mm	3 mm
14	L.lip/E-plane	-2mm	2 mm	+3mm	-2mm	5 mm**

** Greater changes reported

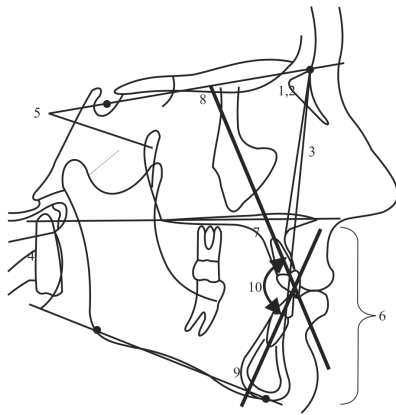


Fig 1: Skeletal & Dental Parameters measured are 1). SNA 2). SNB 3). ANB 4). MMA 5). SN-MP 6). LFH 7). UI-MM 8). UI-SN 9). IMPA 10). Inter-Incisal

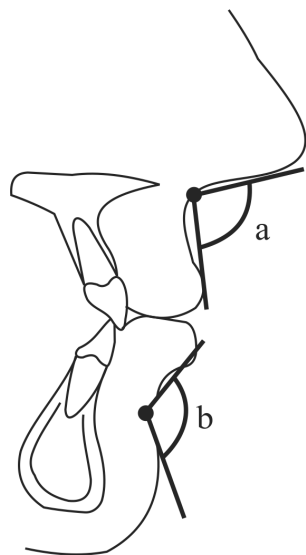


Fig 2: The profile soft tissue angular parameters measured 1). naso-labial angle 2). labio-mental angle

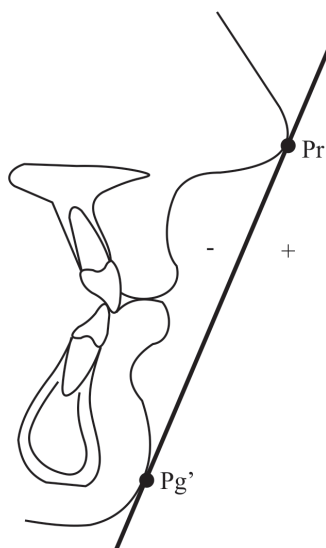


Fig 3: The soft tissue linear parameter measured is Esthetic Plane

prognathic mandible amongst our patient sample. As noted, the mean pre-treatment maxillary-mandibular plane angle value was 33° , showing a tendency towards an associated high angle or increased anterior lower facial height. This was further confirmed by the pre-treatment facial height ratio of 56 percent, which decreased to 53 percent post-treatment. The SN to mandibular plane angle also decreased 4° post-treatment from 37° to 33° respectively.

Pre- & Post-Treatment Dental Measurements:

The dental cephalometric parameters showed that IMPA reduced by 9° following retraction from a pre-treatment mean value of 106° to a mean value of 97° , while the inter-incisal angle increased by 13° from 124° to 137° . The upper incisors also retroclined by a mean value of 7° to the maxillary plane during treatment.

Pre- & Post-Treatment Angular Soft Tissue Measurements:

The naso-labial angle increased from a mean pre-treatment value of 86° to 90° , showing a mean difference of 4° change post-treatment. However, The labio-mental angle showed a slight 2° increase from 124° to 126° during treatment.

Pre- & Post- Treatment Linear Soft Tissue Measurements:

As measured by the esthetic plane, the upper lip retracted from a pre-treatment value of $+2$ mm to -1 mm showing a mean difference of 3mm change during treatment, while the lower lip demonstrated a mean difference of 5mm change post-treatment from a forward position of $+3$ mm to -2 mm during treatment.

Table 1: Mean values of pre- and post treatment cephalometrics

DISCUSSION

The investigations in our study mostly depended on pre- and post treatment hard tissue and soft tissue lateral cephalometric analysis. Normal Caucasian cephalometric values were taken to measure bi-maxillary proclination and facial aesthetic parameters.¹⁶ In our study, all patients selected suffered had procumbent lips and associated dento-alveolar protrusion. The majority our patients complained mainly of prominent protruded incisors and lips. However, Facial attractiveness is due to individual perception. It has no standard perception, and an attractive face perceived by the public may not match the average persons face. As mentioned earlier, we have concentrated mostly on the soft tissue profile changes, and the associated dental and skeletal effects, both antero-posteriorly and vertically. As noted in Table 1, the cephalometric tracings confirmed the presence of lip procumbency with skeletal maxillary protrusion,

and to some degree, mandibular protrusion combined with underlying increased vertical dimensions beyond normal Caucasian standards.

As noted in the study, both upper and lower lip showed linear and angular soft tissue changes with treatment. Our results are in agreement with Sukhia HR¹⁷ and Moseling KP¹⁸ who have also shown linear and angular soft tissue profile changes in bi-maxillary protrusion cases. It has been previously reported by Bills DA¹⁹ that 5.2mm of upper labial segment retraction leads to 2.4mm of upper lip retrusion. In our study Ricketts Esthetic plane²⁰ was used as a linear measurement to verify soft tissue changes post-treatment. Our results are in concordance with the findings of Chung KR et al²¹ and Caplan MJ²² who also showed lip retraction with 1st premolar extractions. As evident, the lower lip retracted greater as compared to the upper lip. Previous studies²³⁻²⁴ have also shown that procumbent lower lips retrace further as compare to the upper lip.

As investigated by Looi LK and Mills JRE²⁵, hard tissue skeletal values show little change with tooth movement. Young T & Smith R²⁶ also concluded that 1st premolar extractions caused insignificant to no skeletal changes with orthodontic treatment. However, in our study the dental values showed significant changes. The upper and lower incisors retroclined when measured with the maxillary and mandibular planes, respectively. As evident, 1st premolar extractions produce an average 14 mm space bi-laterally for anterior segment retraction. Recent studies of Xu TM²⁷ and Tan TJ²⁸ have also shown cephalometric angular reduction in upper and lower incisors following 1st premolar extractions in bi-maxillary protrusion cases. Our study agrees with these findings as significant changes were observed in upper and lower incisor retraction following treatment.

As compared to the anterior-posterior changes, the vertical measurements showed significant changes post-treatment. The maxillary mandibular plane decreased 3° from 33° to 30° post-treatment. This was confirmed by post-treatment reduction in both SN to MP angle and facial height ratio. Our results agree with the findings of Chhibber et al²⁹ and Bravo LA³⁰ who also confirmed reduced vertical dimensions following treatment with first premolar extractions. These effects could be attributed to the class 2 elastics mechanism causing forward mandibular dento-alveolar movement during treatment decreasing the maxillary-mandibular plane angle or due to leveling of the curve of spee during treatment leading to better inter-cuspation of the buccal teeth in centric occlusion.³¹ Most authors quote the wedging-hypothesis³²⁻³³ to justify the decrease in anterior facial height following treatment with 1st premolar extractions. Orce-Romero et al³⁴ also states that premolar extractions causes forward movement of the upper and lower buccal segments leading to decrease

in anterior vertical dimensions. Furthermore, Drummond RA³⁵ has stated that premolar extraction leads to better anterior-posterior and vertical facial esthetics in bi-maxillary protrusion patients post-treatment.

Numerous authors³⁶⁻³⁷ have reported greater angular soft tissue changes in bi-maxillary protrusion treatment. In our study, the angular soft tissue measurements showed significant post-treatment changes. The labio-mental angle increased from a pre-treatment mean value of 124.3° to 126.2° showing a mean difference of 2° respectively. The increased labio-mental angle post-treatment could be due to retraction of the lower incisors. Fitzgerald et al³⁸ calculated the mean naso-labial angle value of 114° ± 10° in Caucasian adults with well-balanced faces. In our study, we have taken the mean value of 100° ± 5° as several studies³⁸⁻³⁹ of pleasing profiles indicate a range of 90° to 120° for the ideal naso-labial angle. The naso-labial angle showed greater differences from a pre-treatment mean value of 86.2° to 90.4° with a mean difference of 4.° Our findings agree with the results of Lo and Hunter⁴⁰ who reported that the greater the maxillary incisor retraction the greater the increase in the naso-labial angle.

Lastly, long term stability of corrected bi-maxillary cases are unpredictable and is dependant on proper incisor overbite and lip competency post-treatment. The presence of dental crowding also complicates correction. Furthermore, the dental and soft tissue angular measurements may be within normal cephalometric values yet there may be presence of protrusion of the incisors and lips. However, other soft tissue measurements such as z-angle and s-line⁴¹ can be used to confirm lip retraction & lower facial profile changes following 1st premolar extraction.

CONCLUSION

On the basis of the results obtained from this study, the soft tissue profile can be altered following 1st premolar extractions with incisor retraction in bi-maxillary proclination patients. Facial profile improvement can be enhanced by dento-alveolar and soft tissue retraction with the associated skeletal reduction in the lower facial height. Thereby the main complaints of incisor and lip protrusion can be addressed following extraction treatment.

REFERENCES

- 1 Carter NE, Slattery DA. Bimaxillary proclination in patients of afro-caribbean origin, *British J Orthod*, 1988, 15(2); 175-84.
- 2 Leonardi R, Annunziata A, Licciardello V, Barbato E, Soft tissue changes following the extraction of premolars in nongrowing patients with bimaxillary protrusion. A systematic review, *Angle Orthod*. 2010; 80(1): 211-16.
- 3 Al Maaitah E, El Said N, Abu Alhaja ES, First premolar extraction effects on upper airway dimension in bimaxillary proclination patients, *Angle Orthod*. 2012; 82(5): 853-59.

- 4 DiBiase AT, Sandler PJ. Does orthodontics damage faces? *Dent Update*, 2001, 28(1), 98-104.
- 5 Langberg BJ, Todd A. Treatment of a class I malocclusion with severe bimaxillary protrusion. *Am J Orthod Dentofac Orthop*, 2004, 126(6); 739-46.
- 6 Ismail SF, Moss JP, Hennessy R. Three-dimensional assessment of the effects of extraction and non-extraction orthodontic treatment on the face, *Am J Orthod Dentofac Orthop*, 2002, 121(3) 244-56.
- 7 Keating PJ, The treatment of bimaxillary protrusion. A cephalometric consideration of changes in the inter-incisal angle and soft tissue profile, *Br J Orthod*. 1986; 13(4): 209-20.
- 8 Tan TJ. Profile changes following orthodontic correction of bimaxillary protrusion with a preadjusted edgewise appliance, *Int. J Adult Orthodon Orthognath Surg*, 1996, 11(3); 239-51.
- 9 Helm S, Kreiborg S, Solow B. Psychosocial implications of malocclusion- a 15 year follow up study in 30-year old danes, *Am J Orthod Dentofac Orthop*, 1985, 87(3); 110-18.
- 10 Tai K, Park JH, Tanino M, Ikeda K, Bimaxillary dentoalveolar protrusion treated with lingual appliances and temporary anchorage devices, *J Clin Orthod*. 2012; 46(12): 739-46.
- 11 Kusnoto J, Kusnoto H. The effect of anterior tooth retraction on lip position of orthodontically treated adult Indonesians, *Am J Orthod Dentofac Orthop*, 2001, 120(3); 304-07.
- 12 James RD. A comparative study of facial profiles in extraction and non-extraction treatment, *Am J Orthod Dentofac Orthop*, 1998, 114(2); 265-76.
- 13 Ramesh G, Pradeep M, Kumar GA, Over-bite and Vertical Changes following First Premolar Extraction in High Angle Cases, *J Contemp Dent Pract*. 2012 Nov 1; 13(6): 812-18.
- 14 Hwang HS, Kim WS, McNamara JA. Ethnic differences in the soft tissue profile of Korean and European-American adults with normal occlusion and well balanced faces. *Angle Orthod*, 2002, 72(2); 72-80.
- 15 Bishara SE, Cummins DM, Jakobsen JR. A computer assisted photogrammetric analysis of soft tissue changes after orthodontic treatment. Part II results. *Am J Orthod Dentofac Orthop*, 1995: 108(1); 38-47.
- 16 Bowman SJ, Johnston LE. The esthetic impact of extraction and non-extraction treatment on Caucasian patients, *Angle Orthod*, 2000, 70(1); 3-10.
- 17 Sukhia HR, Hard and soft tissue profile changes following incisor retraction in bi-maxillary proclination orthodontic cases, *The Journal of The Pakistan Dental Association*, Vol: 14 Issue: 1 Jan-March 2005 26-34.
- 18 Moseling KP, Woods MG. Lip curve changes in females with premolar extraction or non-extraction treatment. *Angle Orthod*, 2004, 74(1); 51-62.
- 19 Bills DA, Handelman CS, Bimaxillary dentoalveolar protrusion: traits and orthodontic correction, *Angle Orthod*. 2005; 75(3): 333-39.
- 20 Ricketts RM, Grummons D, Frontal cephalometrics practical applications, *World J Orthod*. 2004; 5(2): 19-102.
- 21 Chung KR, Choo H, Lee JH, Kim SH, Atypical orthodontic extraction pattern managed by differential en-masse retraction against a temporary skeletal anchorage device in the treatment of bimaxillary protrusion, *Am J Orthod Dentofac Orthop*. 2011 Sep; 140(3): 423-32.
- 22 Caplan MJ, Shivapuja PK. The effect of premolar extractions on the soft tissue profile in adult African American females, *Angle Orthod*, 1997, 67(2); 129-36.
- 23 Kachiwala VA, Kalha AS, Machado G, Soft tissue changes associated with first premolar extractions in adult females, *Aust Orthod J*. 2009; 25(1): 24-29.
- 24 Bilodeau JE, Lane JA, Dilemmas in treating a patient with severe bi lveolar protrusion and a hyperdynamic lip, *Am J Orthod Dentofac Orthop*. 2007; 132(4): 540-49.
- 25 Looi LK, Mills JRE. The effect of two contrasting forms of orthodontic treatment on facial profile. *Am J Orthod Dentofac Orthop*, 1986, 89(1); 507-17.
- 26 Young T, Smith R. Effects of orthodontics on facial profile: A comparison of changes during non-extraction and four premolar extraction treatment. *Am J Orthod Dentofac Orthop*, 1993, 103(3); 452-58.
- 27 Xu TM, Liu Y, Yang MZ, Huang W, Comparison of extraction versus nonextraction orthodontic treatment outcomes for borderline Chinese patients, *Am J Orthod Dentofac Orthop*. 2006; 129(5): 672-77.
- 28 Tan TJ, Profile changes following orthodontic correction of bimaxillary protrusion with a preadjusted edgewise appliance, *Int J Adult Orthodon Orthognath Surg*. 1996; 11(3): 239-51.
- 29 Chhibber A, Upadhyay M, Shetty VS, Mogra S, Cephalometric comparison of vertical changes between Begg and preadjusted edgewise appliances, *Eur J Orthod*. 2011 Dec; 33(6): 712-20.
- 30 Bravo LA. Soft tissue facial profile changes after orthodontic treatment with four premolars extracted. *Angle Orthod*, 1994, 64(4); 31-42.
- 31 Timothy FF, Peter GD. Soft tissue profile changes in late adolescent males, *Angle Orthod*, 1997, 5(1); 373-80.
- 32 Boley JC, Mark JA, Sachdeva RC. Long-term stability of class I premolar extraction treatment. *Am J Orthod Dentofac Orthop*, 2003, 124(3); 277-87.
- 33 Finnoy JP, Wisth PJ. Changes in soft tissue profile during and after orthodontic treatment. *Eur J Orthod*, 1987, 9(2); 68-78.
- 34 Orce-Romero A, Iglesias-Linares A, Cantillo-Galindo M, Yañez-Vico RM, Mendoza-Mendoza A, Solano-Reina E, Do the smiles of the world's most influential individuals have common parameters, *J Oral Rehabil*. 2013; 40(3): 159-70.
- 35 Drummond RA. A determination of cephalometric norms for the Negro race. *Am J Ortho Dentofac Orthop*, 1968, 54(3); 670-82.
- 36 Solem RC, Marasco R, Guitierrez-Pulido L, Nelson G, Three-dimensional soft-tissue and hard-tissue changes in the treatment of bimaxillary protrusion. *Am J Orthod Dentofac Orthop*. 2013 Aug; 144(2): 218-28.
- 37 Trisnawaty N, Ioi H, Kitahara T, Suzuki A, Takahashi I, Effects of extraction of four premolars on vermilion height and lip area in patients with bimaxillary protrusion. *Eur J Orthod*. 2013; 35(4): 521-28.
- 38 Fitzgerald JP, Nanda RS, Currier GF. Evaluation of naso-labial angle. *Am J Orthod Dentofac Orthop*, 1992: 102(1); 328-34.
- 39 Tsai HH. Cephalometric characteristics of bi-maxillary protrusion in early mixed dentition. *J Clin Pediatr Dent*, 2002, 26(4); 363-70.
- 40 Lo FD, Hunter WS. Changes in naso-labial angle related to maxillary incisor retraction. *Am J Orthod Dentofac Orthop*, 2003, 82(4); 384-91.
- 41 Drobocky O, Smith R. Changes in facial profile during orthodontic treatment with extraction of four first premolars. *Am J Ortho Dentofac Orthop*, 1989, 95(4); 220-30.