

# BONE HEALING OF CYST-LIKE PERIAPICAL LESION FOLLOWING SURGICAL ENDODONTICS: A CASE REPORT

<sup>1</sup>MUHAMMAD BADER MUNIR, BDS (Pb), MCPS, FCPS (Pak)

<sup>2</sup>NAVEED IQBAL, BDS (Sindh)

<sup>2</sup>SOBIA MASOOD TIRMAZI, BDS (Pb)

<sup>2</sup>HANNA ABDUL MAJEED, BDS (Pb)

## ABSTRACT

*This article presents a case report of endodontic treatment and apicectomy as well as enucleation of large radicular cyst associated with maxillary right central, lateral and canine teeth accompanying labial expansion. Cystic lesion was removed surgically under local anesthesia and apicectomies were done after the completion of root canal treatment.*

**Key words:** Root canal treatment, Radicular cyst, Enucleation, Apicectomy

## INTRODUCTION

Pulpal tissues can become infected through various ways such as caries or trauma, making the pulpal tissue necrotic. The microbial aggregation or its by-products can infiltrate into periradicular tissues and stimulate the host defense system, resulting in periapical/periradicular tissue destruction.<sup>1</sup>

Differential diagnosis with periapical granuloma, radicular cyst or other pathologies is mandatory and necessitates tissue biopsy; as periapical presentations of the lesion may confuse a practitioner.<sup>2</sup>

Radicular cysts are the most common cystic lesions affecting the jaws. They are most commonly found at the apices of the involved teeth, however they may also be found on the lateral aspects of the roots in relation to lateral accessory root canals. Quite often a radicular cyst remains behind in the jaws after removal of the offending tooth and this is referred to as a residual cyst.<sup>3</sup>

Radicular cysts arise from the epithelial residues in the periodontal ligament as a result of inflammation. They generally result due to pulpal infection following dental caries. Bacteria from the gingival sulci or peri-

odontal pockets have been suggested to reach the root canals of these teeth through severed periodontal blood vessels.<sup>4</sup> Pulpal infection can also occur through exposed dentinal tubules at the cervical root surface, due to gaps in the cemental coating.<sup>5</sup> Microbes have also been claimed to 'seed' in the necrotic pulp via the blood circulation (anachoresis).<sup>6</sup> Initially, the tooth pulp becomes infected and necrotic by an autogenous oral microflora. The endodontic environment provides a selective habitat for the establishment of a mixed, predominantly anaerobic flora. Collectively, this habitat-adapted polymicrobial community residing in the root canal has several biological and pathogenic properties, such as antigenicity, mitogenic activity, chemotaxis, enzymatic histolysis, and activation of host cells. The microbial invaders in the root canal can advance, or their products can egress, into the periapex. In response, the host mounts an array of defenses consisting of several classes of cells, intercellular messengers, antibodies, and effectors molecules. The microbial factors and host defense forces encounter, clash with, and destroy much of the periapical tissue, resulting in the formation of various categories of apical periodontitis lesions. Periapical cysts are a direct sequel to chronic apical periodontitis, but not every chronic

<sup>1</sup> Assistant Professor, Department of Operative Dentistry, de, Montmorency College of Dentistry, Lahore

<sup>2</sup> FCPS Resident, Department of Operative Dentistry, Punjab Dental Hospital/de, Montmorency College of Dentistry, Lahore

**Correspondence:** Dr Naveed Iqbal Bangash. Email: [naveedbangash@yahoo.com](mailto:naveedbangash@yahoo.com) Cell: 03339258464

lesion develops into a cyst. There are two distinct categories of periapical cysts, namely, those containing cavities completely enclosed in epithelial lining, and those containing epithelium-lined cavities that are open to the root canals. The latter was originally described as 'bay cysts' and has been newly designated as 'periapical pocket cysts'. More than half of the cystic lesions are true apical cysts, and the remainder are apical pocket cysts.<sup>7</sup>

The following case report describes an orthograde endodontic treatment of right maxillary central, lateral and canine teeth followed by enucleation and apicectomies.

### CASE REPORT

The patient, 21 years of age attended the Operative and Endodontics department of Punjab Dental Hospital, Lahore for endodontic treatment of the maxillary right central incisor. The patient reported recent occurrence of swelling and pus on the right side of maxillary vestibule and gave the history of trauma on right maxillary central incisor two years back. Crown was broken down and discolored. The patient had no significant medical history. OPG showed radiolucent area above right maxillary central, lateral and canine teeth. (Figure 1) Palpation produced purulent exudates and the mucosa in the region was inflamed. Teeth were not tender to percussion and were not mobile.

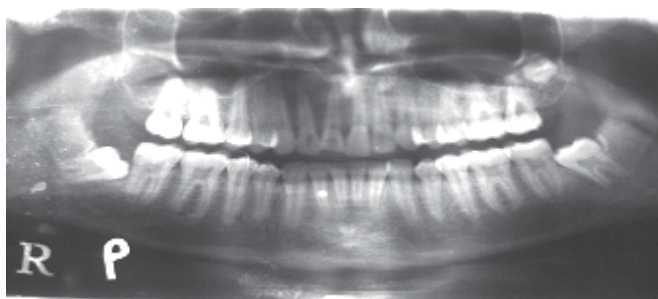


Fig 1

Panaromic radiograph revealed a well-circumscribed radiolucency measuring approximately 20 mm in diameter, extending from right maxillary central incisor to right maxillary canine. (Figure 1)

The patient's clinical and radiographic findings suggested a large cyst-like periradicular lesion, most likely to be an infected radicular cyst.

One visit endodontic treatment was performed for the right maxillary central, lateral and canine teeth. After access cavity preparation, treatment was continued; there was no exudate from the canals. Instrumentation was performed by Flexo-File #15-80, using step-back technique, accompanying with copious irrigation with sterile normal saline between instruments. The working length was determined on the basis of radiographs. Obturation was performed with gutta-percha by lateral condensation technique (Figures 2 & 3). Teeth were permanently restored with composite.

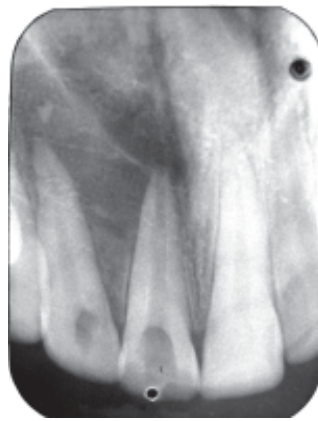


Fig 2

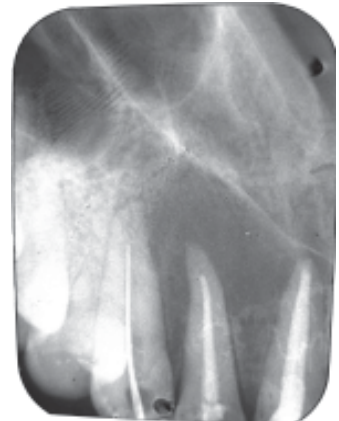

Fig 3

An intra oral approach by raising a trapezoidal flap extending from left maxillary central incisor to right maxillary 1<sup>st</sup> pre molar and the cystic site was exposed, which showed a large bony cavity with missing buccal plate, filled with the cyst. Cystic enucleation was carried out under direct vision and the cyst was removed in-toto and the roots of maxillary central, lateral and canine teeth were resected (Figure 4). Closure was done following hemostasis. Post surgical period was uneventful. The cystic sac was submitted for histopathological examination. Histopathological

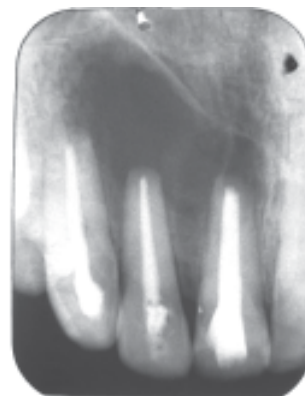

Fig 4

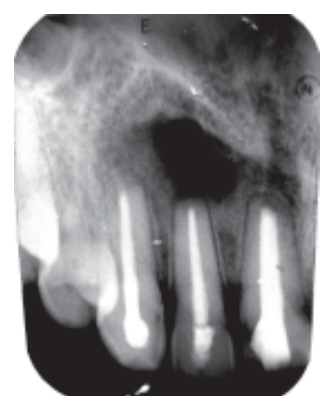


Fig 5

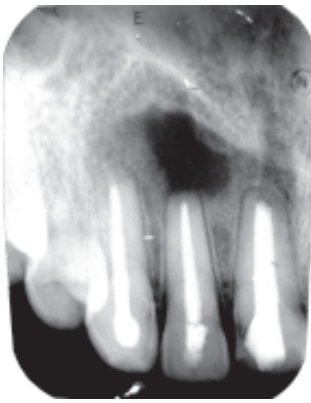


Fig 6

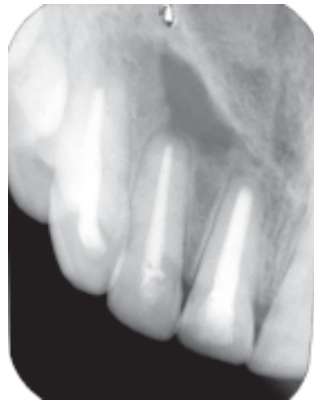

Fig 7

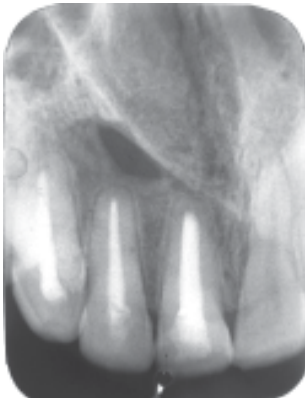


Fig 8

features were consistent with the clinical diagnosis of radicular cyst.

The patient was recalled after 3 (Fig 5), 6 (Fig 6), 9 (Fig 7) and 12 (Fig 8) months for follow up, and had no complaints. Periapical radiographic evaluation demonstrated almost complete bony regression of the lesion. Clinical examination revealed no sensitivity to percussion and palpation.

The patient is still on follow up to access further bony regression of the lesion.

## DISCUSSION

The exact diagnosis was made by histopathological examination. However, the clinical diagnosis of a radicular cyst seemed rational because the lesion accompanied nonvital teeth, was more than 1.6 mm in diameter, and was bordered with a radiopaque line resembling cystic lesions.<sup>8,9</sup> In the present case the radicular cyst had involved right central and lateral incisors and right canine therefore root canal treatment along with enucleation and apicectomies were done. The treatment options available to manage large cysts range

from nonsurgical root canal treatment and/or apical surgery to extraction.<sup>10,11</sup> In some instances, nonsurgical treatment may be ineffective or difficult; those cases may be treated by surgery. It has been indicated that with an observation period of 4 years the complete healing and unsuccessful groups increased while the incomplete and uncertain groups diminished.<sup>12</sup>

## CONCLUSION

In the present case single visit root canal therapy without intra canal medicament followed by enucleation and apicectomies proved successful in promoting healing of a large cyst-like periradicular lesion. The result confirms previous reports demonstrating that large periradicular lesions can respond successfully to endodontic surgery.

## REFERENCES

1. Asgary S, Ehsani S. Endodontic treatment of a large periradicular lesion: A case report. *Iranian Endod J* 2008; 3:4
2. M H K Motamedi. Periapical ameloblastoma – A case report; *British Dental Journal*; 2002; 193:443–45
3. Latoo S, Shah AA, Jan SM, Qadir S, Ahmad I, Purra AR, Malik AH. Radicular Cyst. *JK Science* 2009;11:4
4. Grossman LI. Origin of microorganisms in traumatized, pulpless, sound teeth. *J Dent Res* 1967; 46:551-53
5. Nair PNR. Pathogenesis of Apical Periodontitis and the Causes of Endodontic Failures. *Crit Rev Oral Biol Med* 2004;15(6): 348-81
6. Allard U, Nord CE, Sjöberg L, Strömberg T. Experimental infections with *Staphylococcus aureus*, *Streptococcus sanguis*, *Pseudomonas aeruginosa*, and *Bacteroides fragilis* in the jaws of dogs. *Oral Surg Oral Med Oral Pathol*, 1979;48: 454-62
7. Nair PNR. Non-microbial etiology: periapical cysts sustain post-treatment apical Periodontitis. *Endodontic Topics* 2003;6: 96-113
8. White SC, Pharaoh MJ. *Oral radiology*. 5<sup>th</sup> Edition. St Louis: CV Mosby; 2004. P. 385
9. Wood NK, Goaz PW, Jacobs MC. Periapical radiolucencies. In: Wood NK, Goaz PW. *Differential diagnosis of oral and maxillofacial lesions*. 5<sup>th</sup> Edition. St Louis: CV Mosby;1996. P. 257
10. Garcia CC, Sempere FV, Diago MP, Bowen EM: The post-endodontic periapical lesion: histologic and etiopathogenic aspects. *Med Oral Patol Oral Cir Bucal* 2007; 12:585-90
11. Komori T, Yokoyama K, Takato T, Matsumoto K. Clinical application of the erbium:YAG laser for apicoectomy. *J Endod* 1997, 23:748-50
12. Caliskan MK. Prognosis of large cyst-like periapical lesions following nonsurgical root canal treatment: a clinical review. *Int Endod J*,2004; 37:408–16