

## CAPILLARY HEMANGIOMA OF PALATE: A CASE REPORT

<sup>1</sup>ROOPIKA HANDA, MDS<sup>2</sup>SOHEYL SHEIKH, MDS<sup>3</sup>SHAMBULINGAPPA P, MDS<sup>4</sup>AMIT AGGARWAL, MDS<sup>5</sup>JYOTI MAGO, BDS<sup>6</sup>SIPRA SALARIA, BDS

## ABSTRACT

*Pyogenic granulomas and hemangiomas of oral cavity are well-known benign lesions. Although pyogenic granuloma is known to show a striking predilection for the gingiva and capillary hemangioma for lips, cheek and tongue, palatal occurrence of these lesions is extremely rare. The clinical diagnosis of such an uncommon occurrence can be quite challenging as they sometimes may mimic more serious lesions such as malignancies. This case report presents a rare case of capillary hemangioma of the palatal mucosa.*

**Key Words:** Capillary hemangioma, pyogenic granuloma, oral mucosa.

## INTRODUCTION

Pyogenic granuloma and capillary hemangiomas are well known and commonly occurring benign vascular lesions of the oral cavity.<sup>1</sup> Although hemangiomas of the head and neck are common, these tumors are rarely seen in the oral cavity<sup>2</sup>, especially in the oral soft tissue. As a result, they are not commonly encountered by dental professionals.<sup>3</sup> Hemangiomas are considered to be benign tumors of infancy characterized by a rapid growth phase with endothelial cell proliferation followed by gradual involution.<sup>4</sup> They are composed of

blood vessels and are classified on the basis of their histological appearance as capillary, mixed cavernous, or a sclerosing variety that tends to undergo fibrosis. Hemangiomas occur in the skin of 4-10% of Caucasian new borns with a 3-5 fold greater incidence in females. Dark skinned infants have a lower incidence.<sup>1</sup> No details about the incidence in the Indian population is as yet available.<sup>6</sup>

Pyogenic granulomas of the oral cavity are known to involve the gingiva commonly. It is important to note here that this condition is neither associated with pus nor does it represent a granuloma histologically.<sup>7</sup> In fact on the basis of the histopathological picture alone, it is invariably called lobular capillary hemangioma.<sup>8</sup> Both pyogenic granuloma and hemangioma rarely occur in palatal mucosa. Thus the differentiation between a capillary hemangioma and pyogenic granuloma is somewhat unclear at this time. Hence the question arises, as to whether the term "pyogenic granuloma" should be used as a diagnosis or not. Here we present a case report of capillary hemangioma.

## CASE REPORT

A 25-year-old female reported to the Department of Oral Medicine & Radiology, M.M. College of Dental Sciences & Research, Mullana with a complaint of a

**Corresponding Author:** <sup>5</sup>Dr. Jyoti Mago, Postgraduate student, Department of Oral Medicine and Radiology, M.M. College of Dental Sciences and Research, Mullana, Ambala, Haryana (India) Pin 133203 Phone No. +91-9729421685 (Mobile)  
Email: jyotimago22@gmail.com

1 Assistant Professor, Oral Medicine and Radiology, M.M. College of Dental Sciences and Research, Mullana, Ambala,  
E-mail: roopika77@gmail.com

2 Professor and Head, Oral Medicine and Radiology  
E-mail: sohey1@cliffhanger.com

3 Professor, Oral Medicine and Radiology  
E-mail: pallagatti@hotmail.com

4 Assistant Professor, Oral Medicine and Radiology,  
E-mail: dramitagar1@yahoo.com

6 Post-graduate student, Oral Medicine and Radiology, M.M. College of Dental Sciences and Research, Mullana, Ambala,  
E-mail: jyotimago22@gmail.com

**Received for Publication:** December 7, 2012

**Accepted:** February 21, 2013

gingival swelling. On recording her history, she reported a small but similar lesion 3 months ago during her first month of pregnancy. This was later excised within a month but the lesion reoccurred again 28 days ago and has attained the present visit. The rest of her history was insignificant apart from a history of multiple perioral blisters associated with fever for the past 1 week.

Her medical history was non contributory. Extra oral examination revealed crustations on the upper lip border. There was no associated lymphadenopathy and fever. On intra oral examination there was a pale pink, solitary, exophytic, pedunculated lesion with interdental papilla on the palatal aspect of maxillary central incisors (fig 1). It was measured 2cm x 1.5cm in size and had a distinct border and irregular surface. The surrounding palatal mucosa was normal. On palpation the growth was firm in consistency with no blanching, tenderness, bleeding or pus discharge. A panoramic radiographic examination revealed no abnormality (Fig 2).

Based on the history of pregnancy, a provisional diagnosis of pyogenic granuloma was given. For the extra oral lesion provisional diagnosis of herpes labialis was done. The differential diagnosis for the intra oral lesion was peripheral ossifying fibroma and peripheral giant cell granuloma. The hemogram of the patient was within normal limits. An excisional biopsy was performed under local anaesthesia and subjected to histopathological examination.

Histopathologically, the excised specimen showed few large endothelial cell lined blood vessels and numerous proliferating endothelial cell lined capillaries containing RBC's in lobular pattern separated by fibrous septae in the connective tissue stroma. Chronic inflammatory infiltrate composed predominantly of plasma cells and lymphocytes and few extravasated RBC's were also seen. Thus, this was suggestive of infected capillary hemangioma (fig 3).

The surgical site showed good healing with no further gingival overgrowth after 1 week. No subsequent changes were observed after a follow up of one month (fig 4).

## DISCUSSION

Hemangiomas are common soft tissue tumors that are often congenital or develop in the neonatal period and grow rapidly. They usually cover a large site, may

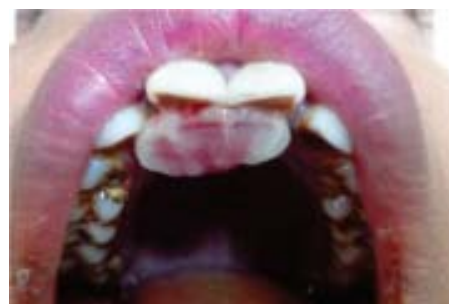

Fig 1: Solitary, exophytic, pedunculated lesion with interdental papilla on the palatal aspect of maxillary central incisors

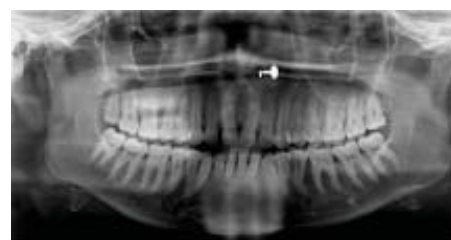

Fig 2: Panoramic radiograph showing multiple irregular calcified structures on left side over ramus of mandible.

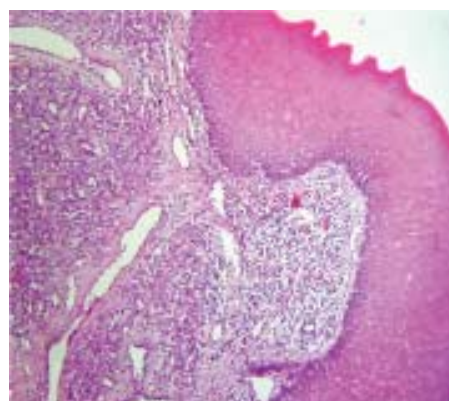


Fig 3: The excised specimen showed few large endothelial cell lined blood vessels and numerous proliferating endothelial cell lined capillaries containing RBC's in lobular pattern separated by fibrous septae in the connective tissue stroma.

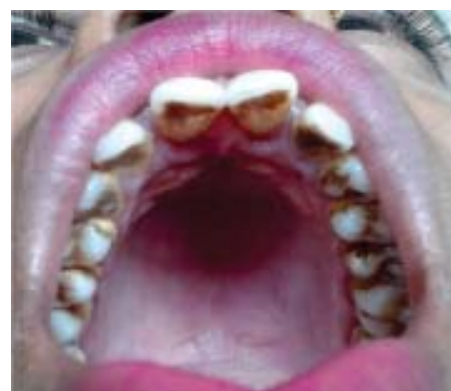

Fig 4: No recurrence after 1 month

be macular or raised and usually resolve progressively in childhood. They may occur in the oral and maxillo-facial region including gingiva, palatal mucosa, lips, jawbone, and salivary glands. Apart from the oral cavity, capillary hemangioma developed at other sites such as eyelid, cheek and cauda equine.

Hemangiomas may mimic other lesions clinically, radiographically and histopathologically. The differential diagnosis of hemangiomas includes pyogenic granuloma, peripheral giant cell granuloma, peripheral ossifying fibroma, chronic inflammatory gingival hyperplasia (epulis), epulis granulomatosa, varicocele, talengec-tasia, and squamous cell carcinoma.<sup>9</sup>

Radiographs are advised to rule out bony destruction suggestive of central variety of hemangioma, malignancy or to identify a foreign body that should need to be removed with the lesion. The patient in our case had a lesion on palate and was diagnosed as pyogenic granuloma. On histopathological examination it was diagnosed as infected capillary hemangioma. As in the present case, pyogenic granuloma ("Lobular Capillary Hemangioma") is a proliferative vascular lesion often clinically confused with hemangioma, unfortunately, as both share the histologic designation "Capillary Hemangioma."

The management of hemangiomas of the oral mucosa varies according to the age of the patient, the size of the lesion, the site of involvement and the clinical nature of the hemangioma. The range of treatment includes steroid therapy, carbon dioxide or argon laser therapy, sclerosing agents, surgical excision with or without ligation of vessels and embolization. Current management consists of '*primum non nocere*' i.e spontaneous involution, steroid therapy and chemotherapy.<sup>1</sup>

In the present case, the lesion was small and was not life threatening in nature on presentation. Radiographically it did not show any bony involvement. Hence, it was decided to treat this case by simple excision under necessary precautions. At 1-week post-surgical follow-up, the wound was observed to be

healing well, and no complications were noted. On a follow up of 1 month, the wound healing was complete and no recurrence was observed.

## CONCLUSION

The term hemangioma is used inconsistently, some sources including vascular malformations, others classifying vascular malformations separately. Haemangioma is of benign origin and behaviour, but haemangioma in the oral cavity is of clinical importance. Attempts to remove them using simple excision may lead to serious medical problems.

Dental surgeons should be aware of the risks while managing these innocent lesions and should take necessary precautions prior to attempts at excision of these lesions as it often mimics other lesion clinically and requires appropriate clinical diagnosis and proper management. In addition, the periodontal surgical management of hemangiomas should be performed with caution because the tissues may bleed profusely intra operatively and post operatively. Early detection and biopsy is necessary to determine the clinical behaviour and potential dentoalveolar complications.

## REFERENCES

1. Rachappa M.M., Triveni M.N.. Capillary hemangioma or pyogenic granuloma: A diagnostic dilemma. Contemporary clinical dentistry, April-June 2010, Vol. 1, issue 2.
2. Bayrak S, Dalsi K, Hamza T. Capillary hemangioma of the palatal mucosa: report of unusual case. SÜ Dishek Fak Derg, 2010; 19: 87-89.
3. Acýkgöz A, Sakallıoglu U, Ozdamar S, Uysal A. Rare benign tumours of oral cavity- capillary hemangioma of palatal mucosa: a case report. *Int J Paediatr Dent* 2000; 10: 161-5.
4. Neville BW, Damm DD, Allen CM, Bouquot JE. Oral & Maxillofacial Pathology. 2nd ed. Saunders Philadelphia, p: 390-2, 2002.
5. Murthy J. Vascular anomalies. *Indian J Plst Surg.* 2005; 38: 56-62.
6. Shafer WG, Hine MK, Levy BM. A textbook of oral pathology. 4<sup>th</sup> ed. Philadelphia: WB Saunders; 1983. p. 359-360.
7. Patil K, Mahima VG, Ambika L. Extralingival pyogenic granuloma. *Indian J Dent Res* 2006; 17: 199-202.
8. Wood NK, Goaz PW. Differential diagnosis of oral and maxillofacial regions. 5<sup>th</sup> ed. Missouri: Mosby; 1997. p. 549-550.